


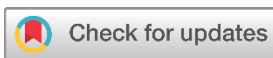Systematic Review

Hydatid Cyst of The Breast: A Systematic Review

Rezheen J. Rashid¹, Khanda A. Anwar², Ayoob A. Mohammed³, Soran H. Tahir³, Ali H. Hasan⁴, Snur Othman^{5*} , Ismael Y. Abdullah^{3,6,7}, Sasan M. Ahmed⁸, Shevan M. Mustafa⁵, Yousif M. Mahmood⁹, Sabah Jalal Hasan⁹, Fakher Abdullah¹⁰, Hussein M. Hamasalih¹¹

1. Department of Radiology, Hiwa Hospital, Sulaymaniyah, Iraq
2. Department of Basic Medical Sciences, College of Medicine, University of Sulaimani, Madam Mitterrand Street, Sulaymaniyah, Iraq
3. College of Medicine, University of Sulaimani, Madam Mitterrand Street, Sulaymaniyah, Iraq
4. Department of Radiology, Sulaimani Directorate of Health, Sulaymaniyah, Iraq
5. Kscien Organization for Scientific Research (Middle East office), Hamdi Street, Azadi Mall, Sulaymaniyah, Iraq
6. Garmian Medical City, Kalar, Iraq
7. Shaheed Khalid Garmiani Hospital, kifri, Iraq
8. Green Apple Organization for Health Awareness, Hamdi Street, Azadi Mall, Sulaymaniyah, Iraq
9. Smart Health Tower, Madam Mitterrand Street, Sulaymaniyah, Iraq
10. Kscien Organization for Scientific Research (Europe office), Rotterdam, Netherlands
11. College of Nursing, University of Sulaimani, Madam Mitterrand Street, Sulaymaniyah, Iraq

* **Corresponding author:** snurothmamns@gmail.com (S. Othman). Doctor City, Building 11, Apartment 50, Zip code: 46001, Sulaymaniyah, Iraq



Keywords:
Echinococcus granulosus
Tapeworm
Cestode
Hydatid cyst
Breast mass

Received: July 20, 2024
Revised: August 16, 2024
Accepted: August 27, 2024
Published: August 31, 2024

Copyright: © 2024 Rashid et al. This is an open access article distributed under the terms of the Creative Commons Attribution License (<https://creativecommons.org/licenses/by/4.0/>), which permits unrestricted use, distribution, and reproduction in any medium, provided the original author and source are credited.

Citation: Rashid RJ, Anwar KA, Mohammed AA, Tahir SH, Hasan AH, Othman S, et al. Hydatid Cyst of The Breast: A Systematic Review. Barw Medical Journal. 2024 Aug 31;2(3):46-52.
<https://doi.org/10.58742/bmj.v2i3.121>

Abstract

Introduction

Due to its rarity, there is limited information regarding breast hydatid disease, mostly derived from case reports. This study aims to review the clinical presentation and management of the disease systematically.

Methods

The PubMed/Medline and Google Scholar were searched with the following keywords: (Breast OR Breasts OR "mammary gland" AND hydatid OR hydatidosis OR echinococcus OR echinococcal OR echinococcosis OR "E. granulosus"). Only English-language studies published in legitimate journals were included. Additional inclusion criteria involved a confirmed diagnosis of breast hydatid cyst, details on presentation, cyst characteristics, and management.

Results

Most cases were reported in India (32.6%) and Turkey (25.6%). The mean age of the patients was 40.88 ± 15.7 years, and all 43 patients were female. Most (69.8%) were asymptomatic, while 25.6% reported pain and 2.3% reported dry skin. Surgery with albendazole was the treatment of choice in 51.2% of the cases, followed by surgery alone in 39.5%. Most cases (65.1%) recovered without complications, whereas one did not and was under follow-up. The recovery status was not mentioned in 14 cases (32.6%).

Conclusion

Breast hydatid cyst is an extremely rare finding that can be asymptomatic in most instances. Surgery combined with albendazole may be the most successful treatment approach.

1. Introduction

Echinococcosis is a zoonotic, parasitic infection caused by the larvae of *Echinococcus granulosus* [1]. The parasite is a tapeworm with an approximate length of 2 to 7 mm [2]. While the disease can occur anywhere, it is considered endemic in several regions, including the Middle East, the Mediterranean, South Africa, America, and Australia [3,4]. The parasite's definitive hosts are wild and domestic canids. Humans can become accidentally infected by direct contact with hosts or by ingesting food contaminated with the parasite's eggs. Upon ingestion, larvae hatch and form cysts that gradually enlarge, triggering a granulomatous reaction [2]. These cysts are known as hydatid cysts (HCs) and may not cause symptoms unless they rupture or pressure nearby structures [5]. Due to its life cycle and close relation to animals, it is important to consider contact with animals as a risk factor during history-taking [4]. This is why people living in rural areas are at a higher risk of being infected by this disease [6]. The liver is the most frequently affected organ, accounting for 55-70% of cases, while the lungs rank as the second most common site (18-35%). Breast HC is exceedingly rare, reported in less than 1% of all HC cases [7]. It usually presents as an enlarging breast mass that has neither pain nor any involvement of the regional lymph node [8]. Due to its rarity, the literature has limited information regarding breast HCs. Therefore, this study aims to review the clinical presentation and management of breast HCs systematically.

2. Methods

2.1. Study Protocols

This study was per the Preferred Reporting Items for Systematic Reviews and Meta-Analyses (PRISMA) 2020 guideline.

2.2. Data sources and search strategy

The PubMed/Medline and Google Scholar were searched with the following keywords: (Breast OR Breasts OR "mammary gland" AND hydatid OR hydatidosis OR echinococcus OR echinococcal OR echinococcosis OR "E. granulosus").

2.3. Eligibility Criteria

Only English-language studies published in legitimate journals [9] were included. Additional inclusion criteria involved a confirmed diagnosis of breast HC, details on presentation, cyst characteristics, and management. Two authors performed the screening to select studies that met the eligibility criteria, and a third author blindly rechecked their work.

2.4. Data items

Data such as first author name, study design, country and year of publication, sample size, patient demography, characteristics of masses, presentation, management, and outcome were extracted from the included studies.

2.5. Data analysis and synthesis

The data were collected in a Microsoft Excel sheet (2019) and descriptively analyzed by Statistical Package for Social Sciences

(SPSS) 26.0 software. The data were presented in frequency, percentage, mean, and standard deviation.

3. Results

3.1. Study Selection

In total, 144 articles were identified in the systematic research. Then, 47 abstract-only and four non-English studies were excluded before further screening. This left 93 articles for further screening, resulting in the removal of 33 studies due to irrelevancy. Within the 60 remaining articles, six were removed since they were incompatible with the inclusion criteria, leaving only 54 studies to be assessed for eligibility. Out of the 54 studies evaluated, 11 were removed due to publishing in predatory journals (Figure 1). Finally, 43 studies were included [8,10-51]. The raw data of each study can be found in Table 1.

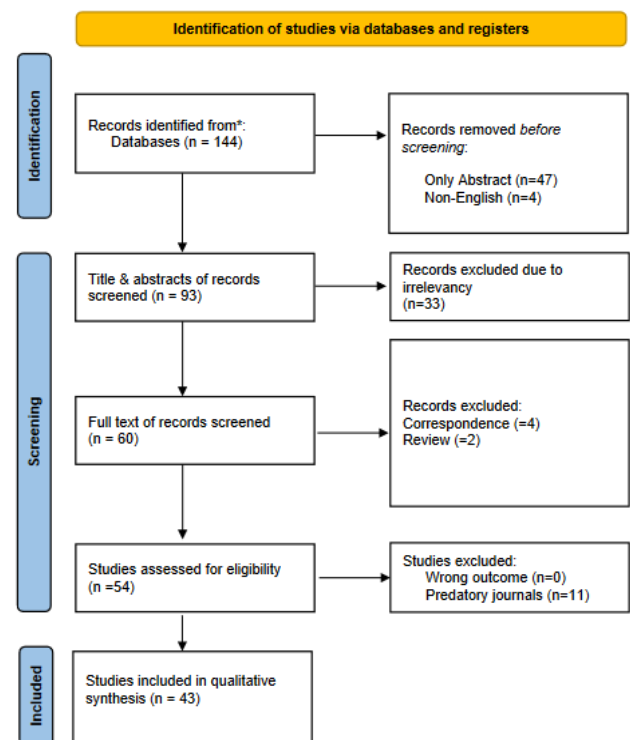


Figure 1. Study selection PRISMA flow chart.

3.2. Main findings

Most cases were reported in India (32.6%) and Turkey (25.6%). The mean age of the patients was 40.88 ± 15.7 years, and all 43 patients were female. Only six patients (14%) reported a history of animal contact, and all cases with known residency (18.6%) lived in rural areas. Out of the 51 masses found, 30 (58.8%) of them were on the left side, 19 (37.2%) on the right, and 2 (4%) were extramammary. The mean size of the breast masses was 4.95 ± 2.91 cm. Most cases (69.8%) were asymptomatic, while 25.6% reported pain and 2.3% reported dry skin. Among the 10

Table 1. The raw data of each study.

Author (reference)	Type of Study	Country	Year	N. Patients	Age	Animal Contact	Residency	Gender	N. Masses	Side of Mass	Presentation	Symptoms	Hydatid serology	Treatment	Outcome
El Moussaoui et al [8]	Case report	Morocco	2020	1	59	N/A	N/A	Female	2	1 Right 1 Left	Symptomatic	Pain	N/A	Surgery with Albendazole	Recovery
Kumar et al [10]	Case report	India	2015	1	31	No	N/A	Female	1	Right	Asymptomatic	N/A	N/A	Surgery alone	N/A
Al Sharei et al [11]	Case report	Jordan	2023	1	38	N/A	N/A	Female	2	Left	Symptomatic	Dry skin	N/A	Surgery with Albendazole	Recovery
Cancelo et al [12]	Case report	Spain	2012	1	70	N/A	N/A	Female	1	Left	Asymptomatic	N/A	N/A	Observation	No recovery
Tadele et al [13]	Case report	Ethiopia	2022	1	18	No	Rural	Female	1	Left	Asymptomatic	N/A	N/A	Surgery with Albendazole	Recovery
Moazeni-Bistgani [14]	Case report	Iran	2016	1	61	Yes	N/A	Female	2	1 Right 1 Left	Symptomatic	Pain	Positive	Surgery alone	Recovery
Alamer et al [15]	Case report	Saudi Arabia	2013	1	66	N/A	N/A	Female	1	Left	Symptomatic	Pain	N/A	Surgery alone	N/A
Acar et al [16]	Case report	Turkey	2003	1	37	N/A	N/A	Female	1	Right	Symptomatic	Pain	Positive	Surgery alone	Recovery
Mesfin et al [17]	Case report	Ethiopia	2023	1	28	N/A	N/A	Female	1	Left	Symptomatic	Pain & Weight loss	N/A	Surgery with Albendazole	N/A
Vega et al [18]	Case report	Spain	1993	1	74	N/A	N/A	Female	1	Right	N/A	N/A	N/A	Surgery alone	N/A
Uncu et al [19]	Case report	Turkey	2007	1	31	N/A	N/A	Female	1	Right	Asymptomatic	N/A	N/A	Surgery with Albendazole	Recovery
Samsami et al [20]	Case report	Iran	2021	1	31	N/A	Rural	Female	2	1 Left 1 Extramammary	Asymptomatic	N/A	Negative	Surgery with Albendazole	Recovery
Gul et al [21]	Case report	Pakistan	2019	1	25	N/A	N/A	Female	1	Right	Asymptomatic	N/A	N/A	Surgery with Albendazole	Recovery
Karataş et al [22]	Case report	Turkey	2013	1	34	N/A	Rural	Female	1	Left	Asymptomatic	N/A	N/A	Albendazole	Recovery
Abu-Mandeel et al [23]	Case report	Jordan	2023	1	38	N/A	N/A	Female	1	Left	Asymptomatic	N/A	N/A	Surgery with Albendazole	Recovery
Dubhashi et al [24]	Case report	India	2023	1	21	N/A	N/A	Female	1	Right	Asymptomatic	N/A	N/A	Surgery with Albendazole	Recovery
Shekh et al [25]	Case report	Syria	2020	1	23	Yes	Rural	Female	1	Left	Asymptomatic	N/A	N/A	Surgery with Albendazole	N/A
Parvej et al [26]	Case report	India	2015	1	65	N/A	N/A	Female	1	Left	Asymptomatic	N/A	N/A	Surgery with Albendazole	Recovery
Elverici et al [27]	Case report	Turkey	2013	1	50	N/A	N/A	Female	1	Left	Asymptomatic	N/A	N/A	N/A	N/A
Sarkar et al [28]	Case report	India	2015	1	58	Yes	Rural	Female	3	Right	Asymptomatic	N/A	Positive	Surgery with Albendazole	Recovery

Alareqi et al [29]	Case report	Yemen	2021	1	23	N/A	N/A	Female	1	Left	Asymptomatic	N/A	N/A	Albendazole	Recovery
Koc et al [30]	Case report	Turkey	2017	1	59	N/A	N/A	Female	1	Left	Symptomatic	Pain	N/A	Surgery alone	N/A
Ines et al [31]	Case report	Tunisia	2022	1	50	N/A	Rural	Female	1	Left	Asymptomatic	N/A	Negative	Surgery alone	Recovery
Önder et al [32]	Case report	Turkey	2011	1	62	N/A	N/A	Female	1	Left	Asymptomatic	N/A	Negative	Surgery with Albendazole	Recovery
Ansari et al [33]	Case report	India	2014	1	30	N/A	N/A	Female	1	Right	Symptomatic	Pain	N/A	Surgery with Albendazole	N/A
Jha et al [34]	Case report	India	2014	1	28	No	Rural	Female	1	Right	Symptomatic	Pain	Positive	Surgery alone	Recovery
Sah et al [35]	Case report	Nepal	2000	1	33	Yes	N/A	Female	1	Left	Asymptomatic	N/A	N/A	Surgery alone	Recovery
Geramizadeh et al [36]	Case report	Iran	2011	1	35	Yes	Rural	Female	1	Left	Asymptomatic	N/A	N/A	Surgery with Albendazole	Recovery
Dogan et al [37]	Case report	Turkey	2005	1	56	N/A	N/A	Female	1	Left	Asymptomatic	N/A	N/A	Surgery with Albendazole	Recovery
Kamali et al [38]	Case report	India	2012	1	42	N/A	N/A	Female	1	Left	Symptomatic	Pain	Positive	Surgery alone	Recovery
Assefa et al [39]	Case report	Ethiopia	2022	1	28	N/A	N/A	Female	1	Left	Asymptomatic	N/A	N/A	Surgery alone	N/A
Gupta et al [40]	Case report	India	1994	1	27	N/A	N/A	Female	1	Left	Asymptomatic	N/A	N/A	Surgery with Albendazole	Recovery
Sharma et al [41]	Case report	India	1997	1	26	N/A	N/A	Female	1	Left	Asymptomatic	N/A	N/A	Surgery alone	N/A
Arikan et al [42]	Case report	Turkey	2004	1	42	N/A	N/A	Female	1	Right	Asymptomatic	N/A	N/A	Surgery alone	N/A
Tutar et al [43]	Case report	Turkey	2006	1	48	N/A	N/A	Female	2	Left	Asymptomatic	N/A	N/A	Surgery with Albendazole	N/A
Sheikh et al [44]	Case report	India	2017	1	45	N/A	N/A	Female	1	Right	Symptomatic	Pain	N/A	Surgery alone	Recovery
Sharma et al [45]	Case report	India	2019	1	35	N/A	N/A	Female	1	Right	Asymptomatic	N/A	N/A	Surgery alone	N/A
Uysal et al [46]	Case report	Turkey	2007	1	32	N/A	N/A	Female	2	1 Right 1 Extramammary	Symptomatic	Pain	N/A	Surgery with Albendazole	Recovery
Maraclan et al [47]	Case report	Turkey	2015	1	31	N/A	N/A	Female	1	Left	Asymptomatic	N/A	Positive	Surgery alone	Recovery
Gupta et al [48]	Case report	India	2014	1	70	N/A	N/A	Female	1	Right	Asymptomatic	N/A	N/A	Surgery with Albendazole	Recovery
Bekele et al [49]	Case report	Ethiopia	2016	1	18	Yes	N/A	Female	1	Left	Asymptomatic	N/A	N/A	Surgery with Albendazole	Recovery
Munshi et al [50]	Case report	India	2017	1	45	N/A	N/A	Female	1	Left	Asymptomatic	N/A	N/A	Surgery alone	Recovery
Napgal et al [51]	Case report	India	2006	1	35	N/A	N/A	Female	1	Right	Asymptomatic	N/A	Positive	Surgery with Albendazole	N/A

N/A; non-available

cases (23.3%) with serology tests, it was positive in seven cases (16.3%). Surgery with albendazole was the treatment of choice in 51.2% of the cases, followed by surgery alone in 39.5%. Most cases (65.1%) recovered without complications, whereas one did not and was under follow-up. The recovery status was not mentioned in 14 cases (32.6%) (Table 2).

Table 2. The baseline characteristics of the study

Variables	Frequency/Percentage
Mean Age (Years)	40.88 ± 15.7
Sex	
Male	0 (0.0%)
Female	43 (100%)
Country of study	
India	14 (32.6%)
Turkey	11 (25.6%)
Ethiopia	4 (9.3%)
Iran	3 (7.0%)
Spain	2 (4.6%)
Jordan	2 (4.6%)
Morocco	1 (2.3%)
Others	6 (14.0%)
Contact with animal	
Yes	6 (14.0%)
No	3 (7.0%)
Not Mentioned	34 (79.0%)
Residency	
Rural	8 (18.6%)
Urban	0 (0.0%)
Not mentioned	35 (81.4%)
Side of masses	
Left side	30 (58.8%)
Right side	19 (37.2%)
Extramammary	2 (4.0%)
Average size of masses	4.95 ± 2.91 cm
Presentation	
Symptomatic	12 (27.9%)
Pain	11 (25.6%)
Dry skin	1 (2.3%)
Asymptomatic	30 (69.8%)
Not mentioned	1 (2.3%)
Cyst rupture during presentation in symptomatic cases	
Yes	0 (0%)
No	12 (100%)
Hydatid serology test	
Positive	7 (16.3%)
Negative	3 (7.0%)
Not mentioned	33 (76.7%)
Treatment	
Surgery	17 (39.5%)
Surgery with Albendazole	22 (51.2%)
Albendazole	2 (4.7%)
Observation	1 (2.3%)
Not Mentioned	1 (2.3%)
Outcome	
Patient recovered with no complication	28 (65.1%)
Patient did not recover	1 (2.3%)
Not Mentioned	14 (32.6%)

4. Discussion

This review documented most cases in India (32.6%), followed by Turkey (25.6%). This can be attributed to livestock breeding being more common in these regions [52]. Among the 43 patients in this study, only nine had their animal contact status determined, of which seven had a positive history of animal contact. Mutafchiyski et al. reported that the average age of patients with breast HCs was 40.5 years, whereas Tavakoli et al. found a mean age of 32 years [53,54]. The mean age of the cases in this study was 40.88 years, which closely aligns with that reported by Mutafchiyski et al. Given animals' critical role in the disease's etiology, much attention is placed on the patient's residency. Moreover, due to poor sanitation and inadequate water drainage, most reported cases originate from rural areas or regions with lower socioeconomic status [55]. In the present study, only eight cases had their place of residency determined, all from rural areas.

The HC occurs in 1-200 per 100,000 individuals [56]. In addition to its rarity, the parasite typically forms fluid-filled cysts, most commonly in the liver, followed by the lung, and occasionally in the brain. An isolated breast HC is exceptionally rare, accounting for only 0.27% of the already limited HC cases [11]. About 51 masses were found among the 43 patients included in this study. Six patients (13.9%) had two cysts, and one (2.3%) presented with three different cysts. The cyst typically goes unnoticed unless it ruptures or compresses adjacent structures [5]. In the current study, 30 patients (69.8%) were asymptomatic, 12 (27.9%) were symptomatic, and the presentation status of one patient (2.3%) was undetermined. The mass can mimic breast cancer, as it is generally hard and painless [11]. If present, rapidly developing symptoms are more indicative of cyst rupture than growth [5]. Out of the 12 symptomatic patients in this study, pain was the most common symptom in 11 patients (25.6%). The cyst (s) was not ruptured in any symptomatic cases.

In the breast, the cyst can mimic phyllode tumors, fibroadenomas, abscesses, or even carcinomas, posing challenges for preoperative diagnosis. Therefore, the majority of breast HC cases necessitate postoperative diagnosis, relying on histopathological confirmation [11]. Ultrasound serves as the gold standard imaging modality for diagnosing HCs due to its ease of use, noninvasiveness, and affordability. Additionally, it offers precise information regarding the cyst's location, condition, and size [57]. Mutafchiyski et al. reported that the average size of a breast HC is 5.5 cm, which is 2 cm larger than the average size reported by Tavakoli et al. [53,54]. In this systematic review, the average cyst size was 4.95 ± 2.91 cm, closely resembling the average size reported by Mutafchiyski et al.

While not commonly employed due to its high rate of false negatives and costliness, serological testing for the hydatid antigen is another diagnostic tool for identifying the disease [11]. In this study, only 10 out of 43 patients conducted the test. Among them, nine patients (64.3%) tested positive for the serological test, while five (35.7%) tested negative. Generally, the treatment of HCs depends on several factors, such as the size of the cyst, its location, and the degree of complications [54].

Treatment approaches can either be surgical, aspiration, chemotherapy, or simply watch and wait [11]. Antiparasitic agents such as albendazole can be given before or after surgery to prevent relapse. They can also be prescribed as an alternative for cases where multiple HCs are present [57]. Among reviewed studies, surgery alone was performed for 17 (39.5%) patients, and surgery combined with albendazole was the treatment in 22 (51.2%) patients. Two cases (4.7%) received only albendazole, and one case (2.3%) was under observation only. In total, 28 patients (65.1%) recovered with no complications. One patient (2.3%), who was under observation, did not recover. The recovery status was unknown for 14 patients (32.6%). This study was constrained by the descriptive nature of the included studies (case reports), which might introduce bias and lack comprehensive insights. Missing data in the included studies could also affect the reliability of the findings.

5. Conclusion

Breast HC is an extremely rare finding that can be asymptomatic in most instances. Surgery combined with albendazole may be the most successful treatment approach.

Declarations

Conflicts of interest: The author(s) have no conflicts of interest to disclose.

Ethical approval: Not applicable, as systematic reviews do not require ethical approval.

Patient consent (participation and publication): Not applicable.

Funding: The present study received no financial support.

Acknowledgements: None to be declared.

Authors' contributions: SO, RJR and KAA significantly contributed to the study's conception and the literature search for related studies. SMA, FA, SJH, and SMM were involved in the literature review, manuscript writing, and data analysis and interpretation. AAM, SHT, AHH, IYA, YMM and HMH were involved in the literature review, the study's design, and the manuscript's critical revision. SO and SMA confirm the authenticity of all the raw data. All authors approved the final version of the manuscript.

Data availability statement: Note applicable.

References

- Baram A, Kakamad FH, Alwan AA. Primary posterior mediastinal hydatid cyst mimicking malignant mediastinal neurogenic tumor. *International Journal of Case Reports and Images* 2014;5(1):54-57. [doi:10.5348/ijcri-2014-01-439-CR-12](https://doi.org/10.5348/ijcri-2014-01-439-CR-12)
- Eckert J, Deplazes P. Biological, epidemiological, and clinical aspects of echinococcosis, a zoonosis of increasing concern. *Clinical microbiology reviews*. 2004;17(1):107-35. [doi:10.1128/CMR.17.1.107-135.2004](https://doi.org/10.1128/CMR.17.1.107-135.2004)
- Sadjjadi SM. Present situation of echinococcosis in the Middle East and Arabic North Africa. *Parasitology international*. 2006 ;55:S197-202. [doi:10.1016/j.parint.2005.11.030](https://doi.org/10.1016/j.parint.2005.11.030)
- Salih, A. M., Ahmed, D. M., Kakamad, F. H., Essa, R. A., Hunar, A., & Ali, H. M. Primary chest wall Hydatid cyst: Review of literature with report of a new case. *International Journal of Surgery Case Reports*. 2016; 41: 404-406. [doi:10.1016/j.ijscr.2017.10.051](https://doi.org/10.1016/j.ijscr.2017.10.051)
- Khanfar N. Hydatid disease: a review and update. *Current Anaesthesia & Critical Care*. 2004 ;15(3):173-83. [doi:10.1016/j.cacc.2004.06.002](https://doi.org/10.1016/j.cacc.2004.06.002)
- Deplazes P, Eckert J. Veterinary aspects of alveolar echinococcosis—a zoonosis of public health significance. *Veterinary parasitology*. 2001;98(1-3):65-87. [doi:10.1016/S0304-4017\(01\)00424-1](https://doi.org/10.1016/S0304-4017(01)00424-1)
- Sachar S, Goyal S, Sangwan S. Uncommon locations and presentations of hydatid cyst. *Annals of medical and health sciences research*. 2014;4(3):447-52. [doi:10.4103/2141-9248.133476](https://doi.org/10.4103/2141-9248.133476)
- El Moussaoui K, Lakhdar A, Baidada A, Kherbach A. Hydatid cyst of the breast: case report. *International Journal of Surgery Case Reports*. 2020 ;77:325-8. [doi:10.1016/j.ijscr.2020.10.109](https://doi.org/10.1016/j.ijscr.2020.10.109)
- Mohammed, K. K., Hama, J. I., & Kakamad, F. H. (2024). Beyond Beall's list: The need for contemporary evaluation tools in predatory publishing research. *Learned Publishing*, 37(2), 157-158. [doi:10.1002/leap.1602](https://doi.org/10.1002/leap.1602)
- Kumar A, Gaurav K, Chandra G, Tiwary AK, Bhagat S, Sarawgi M. A rare case of isolated hydatid cyst of breast. *International Journal of Surgery Case Reports*. 2015 ;7:115-8. [doi:10.1016/j.ijscr.2014.10.093](https://doi.org/10.1016/j.ijscr.2014.10.093)
- Al Sharei A, Abu-Jeyyab M, Al-Khalailah M, Al-Awabdeh M, Al-Asbahi H, Al-Dwairy S, et al. Bilateral hydatid cyst of the breast: a case report of the literature. *Annals of Medicine and Surgery*. 2023 ;85(6):2981-4. [doi:10.1097/MS9.0000000000000642](https://doi.org/10.1097/MS9.0000000000000642)
- Cancelo MJ, Martín M, Mendoza N. Preoperative diagnosis of a breast hydatid cyst using fine-needle aspiration cytology: a case report and review of the literature. *Journal of medical case reports*. 2012 ;6:1-4. [doi:10.1186/1752-1947-6-293](https://doi.org/10.1186/1752-1947-6-293)
- Kassahun Tadele A, Israel Korga T, Melis Nisiro A, Abebe Ayele S. Rare case report on hydatid cyst of breast. *Pathology and Laboratory Medicine International*. 2022 ;33-6. [doi:10.2147/PLMI.S380081](https://doi.org/10.2147/PLMI.S380081)
- Moazeni-Bistgani M. Isolated hydatid cyst of the breast that developed after breast feeding. *Journal of Surgical Case Reports*. 2016 ;2016(5):rjw071. [doi:10.1093/jscr/rjw071](https://doi.org/10.1093/jscr/rjw071)
- Alamer A, Aldhilan A, Mankanjuola D, Alkushi A. Preoperative diagnosis of hydatid cyst of the breast: a case report. *Pan African Medical Journal*. 2013 ;14(1). [doi:10.11604/pamj.2013.14.99.2396](https://doi.org/10.11604/pamj.2013.14.99.2396)
- Acar T, Gömcel Ş, Güzel K, Yazgan A, Aydoğan R. Isolated hydatid cyst of the breast. *Scottish medical journal*. 2003 ;48(2):52-3. [doi:10.1177/003693300304800208](https://doi.org/10.1177/003693300304800208)
- Mesfin T, Sahiledengle B, Taha M, Nigusu F, Seyoum K, Geta G, et al. Isolated breast hydatid cyst: A case report. *Clinical Case Reports*. 2023 ;11(12). [doi:10.1002/ccr3.8183](https://doi.org/10.1002/ccr3.8183)
- Vega A, Ortega E, Cavada A, Garijo F. Hydatid cyst of the breast: mammographic findings. [doi:10.2214/ajr.162.4.8140999](https://doi.org/10.2214/ajr.162.4.8140999)
- Uncu H, Erekl S. Hydatid cyst of the breast. *Acta Chirurgica Belgica*. 2007 ;107(5):570-1. [doi:10.1080/00015458.2007.11680127](https://doi.org/10.1080/00015458.2007.11680127)
- Samsami M, Qaderi S, Bagherpour JZ, Lucero-Priso III DE. A case report of primary isolated extrahepatic hydatid cyst of the soft tissues of the breast and thigh. *International journal of surgery case reports*. 2021 ;79:475-8. [doi:10.1016/j.ijscr.2021.01.087](https://doi.org/10.1016/j.ijscr.2021.01.087)
- Gul N, Ali A, Umer US, Khan AN, Ghaus SG, Alam S, Abid H. Isolated hydatid cyst in right breast. *Journal of Rehman Medical Institute*. 2019 Jul 10;5(2):23-4. <https://jrmi.pk/article/view/221>
- Karataş T, Kanlıöz M, Akın M. Breast hydatid cyst mimicking fibroadenoma and malignancy: A case report. *Turkish Journal of Surgery/Ulusal cerrahi dergisi*. 2013;29(3):144. [doi:10.5152/UCD.2013.2140](https://doi.org/10.5152/UCD.2013.2140)
- Abu-Mandeel E, Mahmoud MM, Azizieh O. The "serpent sign"—A classical sign in a nonclassical location: A case report of breast hydatid cyst. *Radiology Case Reports*. 2023 ;18(3):1329-33. [doi:10.1016/j.radcr.2022.12.057](https://doi.org/10.1016/j.radcr.2022.12.057)
- Dubhashi SP, Mehra B, Senthilkumaran K, Meshram N. Primary Hydatid Breast Disease: A Case Report and Review of the Literature. *Medical Journal of Dr. DY Patil University*. 2023;16(6):978-80. [doi:10.4103/mjdrdypu.mjdrdypu.419_21](https://doi.org/10.4103/mjdrdypu.mjdrdypu.419_21)
- Shekh ZA. Hydatid disease—An unusual cause of a breast cyst: Case report. *International Journal of Surgery Case Reports*. 2020 ;68:178-9. [doi:10.1016/j.ijscr.2020.02.066](https://doi.org/10.1016/j.ijscr.2020.02.066)

26. Mujawar P, Suryawanshi KH, Nikumbh DB. Cytodiagnosis of isolated primary hydatid cyst of breast masquerading as a breast neoplasm: A rare case report. *Journal of Cytology*. 2015 ;32(4):270-2. [doi:10.4103/0970-9371.171248](https://doi.org/10.4103/0970-9371.171248)
27. Elverici E, Barça AN, Erhuner Z, Sayın B. Hydatid cyst: an unusual solid breast mass. *Clinical Imaging*. 2013 ;37(3):577-9. [doi:10.1016/j.clinimag.2012.09.002](https://doi.org/10.1016/j.clinimag.2012.09.002)
28. Sarkar S, Choudhuri T, Kumar S, Panja S, Mukherjee M. An unusual case of primary hydatid cyst of the Breast and chest wall. *Hellenic Journal of Surgery*. 2015 ;87:497-500. [doi:10.1007/s13126-015-0267-5](https://doi.org/10.1007/s13126-015-0267-5)
29. Alareqi AA, Alshoabi SA, Alhazmi FH, Hamid AM, Alsharif WM, Gameraddin MB. A rare phenotype of breast hydatid cyst causing misdiagnosis and unnecessary intervention: a case report. *Radiology Case Reports*. 2021 ;16(11):3226-30. [doi:10.1016/j.radcr.2021.07.055](https://doi.org/10.1016/j.radcr.2021.07.055)
30. Koc A, Sarici IS, Vurdem UE, Karabiyik O, Gumus UO. Unusual presentation of hydatid cyst in breast with magnetic resonance imaging findings. *Case Reports in Medicine*. 2017 ;2017. [doi:10.1155/2017/6237435](https://doi.org/10.1155/2017/6237435)
31. Ines M, Mariem BL, Marwa M, Amina BS, Chiraz H. Isolated breast hydatid cyst: Imaging features. *Clinical Case Reports*. 2022 ;10(9):e6362. [doi:10.1002/ccr3.6362](https://doi.org/10.1002/ccr3.6362)
32. Önder A, Kapan M, Girgin S, Akgül ÖL, Önder H, Akyüz Y. Isolated primary hydatid cyst of the breast: Case report. *J Breast Health*. 2012 ;8:152-4. [doi:N/A](https://doi.org/10.1007/s12262-012-0475-y)
33. Ansari MM, Haleem S, Ali WM, Enzang LJ, Ali SS, Meet SK. Low tension breast hydatid cyst—A case report. *Journal of infection and public health*. 2014;7(3):233-6. [doi:10.1016/j.jiph.2014.01.008](https://doi.org/10.1016/j.jiph.2014.01.008)
34. Jha A, Gupta P, Wahab S, Chauhan N, Haroon M, Raghuvanshi RS, et al. Sonographic diagnosis of primary hydatid disease in the breast: the scroll sign. *Journal of Clinical Ultrasound*. 2014 Oct;42(8):502-4. [doi:10.1002/jcu.22160](https://doi.org/10.1002/jcu.22160)
35. Sah SP, Agrawal CS, Khan IR, Rani S. Hydatid cyst presenting as a breast lump. *Southeast Asian J Trop Med Public Health*. 2000 ;31(1):185-6. [doi:N/A](https://doi.org/10.1007/s12262-012-0475-y)
36. Geramizadeh B, Makarempour A, Talei A. Primary isolated hydatid cyst of breast. *Breast Journal*. 2011 ;17(3). [doi:10.1111/j.1524-4741.2011.01084.x](https://doi.org/10.1111/j.1524-4741.2011.01084.x)
37. Basak Erguvan Dogan, Tukul S, Koray Ceyhan. Hydatid Cyst of the Breast. *Current problems in diagnostic radiology*. 2005 ;34(5):204–5. [doi:10.1067/j.cpradiol.2005.06.004](https://doi.org/10.1067/j.cpradiol.2005.06.004)
38. Kamali NI, Raza MH, Rab AZ, Akhtar S. Isolated hydatid cyst of the breast—A case report. *Indian Journal of Surgery*. 2013 ;75:150-1. [doi:10.1007/s12262-012-0475-y](https://doi.org/10.1007/s12262-012-0475-y)
39. Assefa W, Dessalegn M, Admassu S, Molla B. Breast hydatid cyst presented as a fluctuant painless lump mimicking galactocele: A case report. *International Journal of Infectious Diseases*. 2022 ;125:228-30. [doi:10.1016/j.ijid.2022.11.004](https://doi.org/10.1016/j.ijid.2022.11.004)
40. Gupta A, Jain BK, Taneja K, Navjeevan, Bhargava SK. Hydatid Cyst of the Breast. *Tropical doctor*. 1994 ;24(4):173–3. [doi:10.1177/004947559402400414](https://doi.org/10.1177/004947559402400414)
41. Sharma MC, Karak AK, Talwar S, Mirdha BR. Primary hydatid cyst of the breast: A case report. *Surgery today*. 1997 ;27(12):1188–90. [doi:10.1007/BF02385693](https://doi.org/10.1007/BF02385693)
42. Arikan S, Yucel AF, Barui G, Kocakusak A. Hydatid disease in the breast: a case report. *Acta Chirurgica Belgica*. 2004 ;104(4):473-5. [doi:10.1080/00015458.2004.11679600](https://doi.org/10.1080/00015458.2004.11679600)
43. Tutar N, Cakir B, Geyik E, Tarhan NC, Niron EA. Hydatid cysts in breast: mammography and ultrasound findings. *The British journal of radiology*. 2006 ;79(946):e114-6. [doi:10.1259/bjr/33156239](https://doi.org/10.1259/bjr/33156239)
44. Sheikh S, Akhter R, Bhat S, Wani R. Primary hydatid disease of breast: a case report. *Journal of Parasitic Diseases*. 2017 ;41:908-11. [doi:10.1007/s12639-017-0903-9](https://doi.org/10.1007/s12639-017-0903-9)
45. Sharma N, Sharma RA, Sharma S. Case Report: Hydatid Cyst in Breast. *Indian Journal of Surgery*. 2021 ;83(Suppl 2):523-4. [doi:10.1007/s12262-019-01956-7](https://doi.org/10.1007/s12262-019-01956-7)
46. Uysal M, Kilic D, Findikcioglu A, Tarim A, Kocer NE. Coexistence in unusual locations of hydatid cysts: thigh, breast and lung involvement. *International Journal of Infectious Diseases*. 2007 ;11(5):470-2. [doi:10.1016/j.ijid.2007.01.004](https://doi.org/10.1016/j.ijid.2007.01.004)
47. Maralcan G, Özaraç MC. Breast hydatid cyst: An unusual breast lump: Memede hidatik kist: Nadir bir meme kitlesi. *European Journal of Therapeutics*. 2015;21(4):265-7. [doi:10.5578/GMJ.10815](https://doi.org/10.5578/GMJ.10815)
48. Gupta S, Verma DK, Kumar R. A rare presentation of hydatid disease: Breast lump. *Journal of Case Reports*. 2015 ;4(2):331-3. [doi:10.17659/01.2014.0083](https://doi.org/10.17659/01.2014.0083)
49. Bekele A, Firew A. A rare case of hydatid cyst disease of the breast: a case report and review of literature. *Ethiopian Medical Journal*. 2016 ;54(1):37-40. [doi:N/A](https://doi.org/10.1007/s13126-015-0267-5)
50. Munshi SK, Dey P, Agarwal R, Sarkar S, Chowdhury DB, Ray D. Primary hydatid disease of breast causing diagnostic difficulty; A rare case report. *Journal of Surgical Arts*. 2017 ;10(2):41-3. [doi:N/A](https://doi.org/10.1007/s13126-015-0267-5)
51. Nagpal V, Kohli K, Chowdhary A, Kumar A, Andley M, Ravi B. Breast lump as a presentation of a hydatid disease. *Tropical doctor*. 2006 ;36(1):57-8. [doi:10.1258/0049475067755988](https://doi.org/10.1258/0049475067755988)
52. Tamarozzi F, Legnardi M, Fittipaldo A, Drigo M, Cassini R. Epidemiological distribution of *Echinococcus granulosus* s. l. infection in human and domestic animal hosts in European Mediterranean and Balkan countries: A systematic review. *PLoS neglected tropical diseases*. 2020;14(8):e0008519. [doi:10.1371/journal.pntd.0008519](https://doi.org/10.1371/journal.pntd.0008519)
53. Mutafchyski VM, Popivanov GI, Tabakov MS, Vasilev VV, Kjossev KT, Cirocchi R, et al. Cystic echinococcosis of the breast—diagnostic dilemma or just a rare primary localization. *Folia Medica*. 2020 ;62(1):23-30. [doi:10.3897/foamed.62.e47740](https://doi.org/10.3897/foamed.62.e47740)
54. Tavakoli M, Rastegar YF, Laein AF, Farrok D. Hydatid cyst of the breast: a case series and review of the literature. *Iranian Red Crescent Medical Journal*. 2018 ;20(3). [doi:10.5812/ircmj.29972](https://doi.org/10.5812/ircmj.29972)
55. Ahmad S, Jalil S, Saleem Y, Suleman BA, Chughtai N. Hydatid cysts at unusual sites: reports of two cases in the neck and breast. *JPMA. The Journal of the Pakistan Medical Association*. 2010 ;60(3):232–4. [doi:N/A](https://doi.org/10.1007/s12262-012-0475-y)
56. Stojkovic M, Rosenberger K, Kauczor HU, Junghanss T, Hosch W. Diagnosing and staging of cystic echinococcosis: how do CT and MRI perform in comparison to ultrasound?. *PLoS neglected tropical diseases*. 2012 ;6(10):e1880. [doi:10.1371/journal.pntd.0001880](https://doi.org/10.1371/journal.pntd.0001880)
57. Parkoohi PI, Jahani M, Hosseinzadeh F, Taghian S, Rostami F, Mousavi A, et al. Epidemiology and clinical features of hydatid cyst in Northern Iran from 2005 to 2015. *Iranian journal of parasitology*. 2018 ;13(2):310. [doi:N/A](https://doi.org/10.1007/s12262-012-0475-y)