


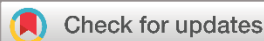## Systematic Review

# Revisiting Pulmonary Sporotrichosis: A Comprehensive Systematic Review of an Overlooked Fungal Infection

Fahmi H. Kakamad<sup>1\*</sup> , Harem K. Ahmed<sup>2</sup>, Hadi Mohammed Abdullah<sup>3</sup>, Bnar J. Hama Amin<sup>2</sup>, Fattah H. Fattah<sup>1</sup>, Khanda A. Anwar<sup>4</sup>, Hemin S. Mohammed<sup>5</sup>, Fakher Abdullah<sup>6</sup>, Tomas M. Mikael<sup>7</sup>, Suhaib H. Kakamad<sup>8</sup>, Yousif M. Mahmood<sup>9</sup>, Marwan N. Hassan<sup>9</sup>, Hiwa O. Abdullah<sup>10</sup>, Berun A. Abdalla<sup>10</sup>

1. College of Medicine, University of Sulaimani, Madam Mitterrand Street, Sulaymaniyah, Iraq
2. Shar Teaching Hospital, Department of Medicine, Sulaymaniyah, Iraq
3. Faruq Medical City, Department of Medicine, Sulaymaniyah, Iraq
4. Department of Basic Medical Sciences, College of Medicine, University of Sulaimani, Madam Mitterrand Street, Sulaymaniyah, Iraq
5. Xzmat polyclinic, Rizgari, Kalar, Iraq
6. Kscien Organization for Scientific Research (Europe office), Rotterdam, Netherlands
7. Kscien Organization for Scientific Research (Middle East office), Hamdi Street, Azadi Mall, Sulaymaniyah, Iraq
8. Department of Immunology and Hematology, College of Medicine, Kurdistan University of Medical Science, Sanandaj, Iran
9. Smart Health Tower, Madam Mitterrand Street, Sulaymaniyah, Iraq
10. Department of Biology, College of Education, University of Sulaimani, Madam Mitterrand Street, Sulaymaniyah, Iraq

\* Corresponding author: [fahmi.hussein@univsul.edu.iq](mailto:fahmi.hussein@univsul.edu.iq) (F.H. Kakamad). Doctor City, Building 11, Apartment 50, Zip code: 46001, Sulaimani, Iraq



## Keywords:

Sporotrichosis  
Sporothrix  
Pulmonary infection  
Immunocompromise  
HIV  
Tropical regions

Received: August 1, 2024

Revised: August 23, 2024

Accepted: September 10, 2024

Published: September 18, 2024

Copyright: © 2024 Kakamad et al. This is an open access article distributed under the terms of the Creative Commons Attribution License (<https://creativecommons.org/licenses/by/4.0/>), which permits unrestricted use, distribution, and reproduction in any medium, provided the original author and source are credited.

Citation: Fahmi HK, Ahmed HK, Abdullah HM, Amin BJH, Fattah FH, Anwar KHA, et al. Revisiting Pulmonary Sporotrichosis: A Comprehensive Systematic Review of an Overlooked Fungal Infection. Barw Medical Journal. 2024 Sep 18;2(3):85-97. <https://doi.org/10.58742/bmj.v2i3.120>

## Abstract

### Introduction

Pulmonary sporotrichosis (PST) is a rare and neglected but severe disease. Its optimal management remains challenging, as recommendations are primarily derived from case reports. This study summarizes PST patients' presentation, diagnosis, management, and outcome.

### Methods

Studies were identified through a search on Google Scholar and PubMed. The collected data included study characteristics, demographic data, risk factors, comorbidities, clinical status, presentations, imaging findings, diagnostic methods, disease locality, fungal species, treatment methods, complications, ICU admission status, and outcomes.

### Results

Most of the studies were conducted in the USA (71.7%). In total, 34.7% of the cases were smokers, 30.7% had occupational exposure to dust and soil, 5.3% had contact with pets or roses or wooden materials, and 2.7% had environmental exposure. Overall, 32% of the patients were alcoholic, 29.3% had bacterial infections, 24% had respiratory or pulmonary diseases, and 17.3% were found to have HIV. The most frequently reported symptom was coughing (61.3%). The most common imaging finding was cavitary lesions (53.3%). The most commonly utilized diagnostic approach was sputum culture (69.3%). A combined conservative regimen was the treatment of choice in 26 patients (34.7%). The survival rate was 69.3%, with a recurrence rate of 5.8%.

### Conclusion

The coexistence of multiple risk factors may trigger the disease. Its low incidence in endemic areas suggests the potential for missed or misdiagnosed cases. Treatment approaches include a combined conservative regimen or in combination with surgery. The survival rate is high, but the mortality rate should not be overlooked.

## 1. Introduction

Sporotrichosis is a subacute or chronic subcutaneous mycosis in tropical and subtropical regions. It is caused by dimorphic fungi of the genus *Sporothrix* [1,2]. The primary route of infection involves the etiological agent traumatically inoculating the subcutaneous tissues while handling soil or other organic materials containing conidia. Additionally, zoonotic transmission, particularly from infected cats, and inhalation of fungal conidia from the environment are different modes of infection [3]. In addition to the cutaneous form, the disease has rare manifestations, including osteoarticular, mucosal, central nervous system, and pulmonary involvement [1]. Pulmonary sporotrichosis (PST) is a rare manifestation with two distinct forms: primary and multifocal. Patients with the primary form typically have underlying respiratory conditions, primarily chronic obstructive pulmonary disease (COPD). In contrast, those with the multifocal form are mostly immunosuppressed, like diabetic, alcoholic, and HIV patients. The respiratory symptoms are not distinctive and can mimic those of tuberculosis (TB) and other endemic systemic mycoses [4]. This condition has gained increased recognition in recent decades due to the rise in reported cases. Early detection can prevent invasive treatment and complications [4-6]. Determining the optimal management for PST remains a challenge. Treatment recommendations are primarily derived from limited evidence in case reports, as conducting randomized controlled trials has been impractical [4].

This systematic review aims to summarize the presentation, diagnosis, management, and outcome of patients with PST. The reviewed studies were confirmed to have been published in legitimate journals [7]

## 2. Methods

### 2.1 Data sources and literature search

The study followed the guidelines of the Preferred Reporting Items for Systematic Reviews and Meta-Analyses (PRISMA). Studies published up to June 1, 2024, were identified through a comprehensive search on Google Scholar and PubMed. The search strategy included the following keywords: (pulmonary OR lung OR respiratory AND sporotrichosis OR rose gardener OR sporothrix OR sporotrichum). The search was limited to human studies published in English without date restriction.

### 2.2 Eligibility criteria

The inclusion criteria were confirmed cases of PST and studies that addressed its presentation, diagnosis, and treatment. Review articles, studies with incomplete data, and those published in journals on warning lists were excluded.

### 2.3 Study selection process

Initially, a researcher reviewed the titles and abstracts of the identified studies, followed by full-text screening based on eligibility criteria. A second researcher then re-checked this work to correct errors and reduce bias. Subsequently, eligible studies were selected for inclusion. In instances of disagreement,

a third author intervened to resolve the issues through discussion and deliberation.

### 2.4 Data extraction

One author extracted the data, which was then independently reviewed by another author to ensure accuracy. The data collected from each study included multiple parameters such as the first author's name, publication year, study affiliation and design, demographic characteristics, risk factors, comorbidities, clinical status, presentations, imaging findings, diagnostic methods, disease focality, fungal species, treatment methods, complications, intensive care unit (ICU) admission status, and outcomes.

### 2.5 Statistical Analysis

The extracted data was collected in an Excel Sheet (2019) and then analyzed for qualitative synthesis (descriptive) using the Statistical Package for the Social Sciences (SPSS, v. 27, IBM Co.). The data was presented as frequency, percentage, mean, standard deviation, or median with range.

## 3. Results

### 3.1 Study selection

The systematic search identified 87 studies. After eliminating duplicates (10), studies with incomplete data (3), and non-English articles (3), the titles and abstracts of 71 articles were screened. Of these, one study was excluded for being irrelevant. Full-text screening of the remaining 70 articles led to the exclusion of 24 more. Ultimately, 46 eligible articles comprising 75 PST cases were included in the systematic review [1,2,4-6,8-48]. A PRISMA flow chart illustrating this process is provided in Figure 1.

### 3.2 Characteristics of the Studies

Most of the studies were conducted in the USA (71.7%), followed by Brazil (8.7%). Case reports constituted the majority of studies (91.3%), followed by three case series (6.5%) and one cohort study (2.2%) (Tables 1 and 2).

### 3.3 Patient demography and clinical status

The patients' ages ranged from 11 to 79, with a mean of 45.8. The gender distribution was predilected toward males (80%), with a male-to-female ratio of 4:1. In total, 34.7% of the cases were smokers, 30.7% had occupational exposure to dust and soil, 5.3% had contact with pets or roses or wooden materials, and 2.7% had environmental exposure. Regarding comorbidities and health issues, 32% of the patients were alcoholic, 29.3% had bacterial infections, 24% had respiratory or pulmonary diseases, and 17.3% were found to be infected with human immunodeficiency virus (HIV). Only three cases (4%) had a positive history of the disease. Nineteen cases (25.3%) were known to be immunocompromised (Table 2).

### 3.4 Disease presentation, diagnosis, and treatment

The raw data for each study can be found in Tables 3 and 4. The most frequently reported symptom was coughing, occurring in 46 patients (61.3%). Other common symptoms included fever in 36 patients (48.0%), weight loss in 34 patients (45.3%), and malaise in 30 patients (40.0%). The most frequent imaging finding was cavitory lesions in 40 patients (53.3%). Lung infiltration was identified in 26 patients (34.7%), pulmonary nodules in 10 patients (13.3%), fibrosis in 7 patients (9.3%), and consolidation in 4 patients (5.3%). In most cases, the diagnostic

conservative regimen plus surgical intervention in 11 patients (14.6%). Surgical intervention alone was employed in one patient (1.3%), while six patients (8.0%) received no treatment or the data was unavailable. Admission to the ICU was required for five patients (6.7%). The overall survival rate was 69.3%; however, 15 patients (20.0%) succumbed to the disease. The outcome of the remaining eight patients (10.7%) were unavailable. Among the survived cases, three patients (5.8%) experienced a disease recurrence (Table 5).

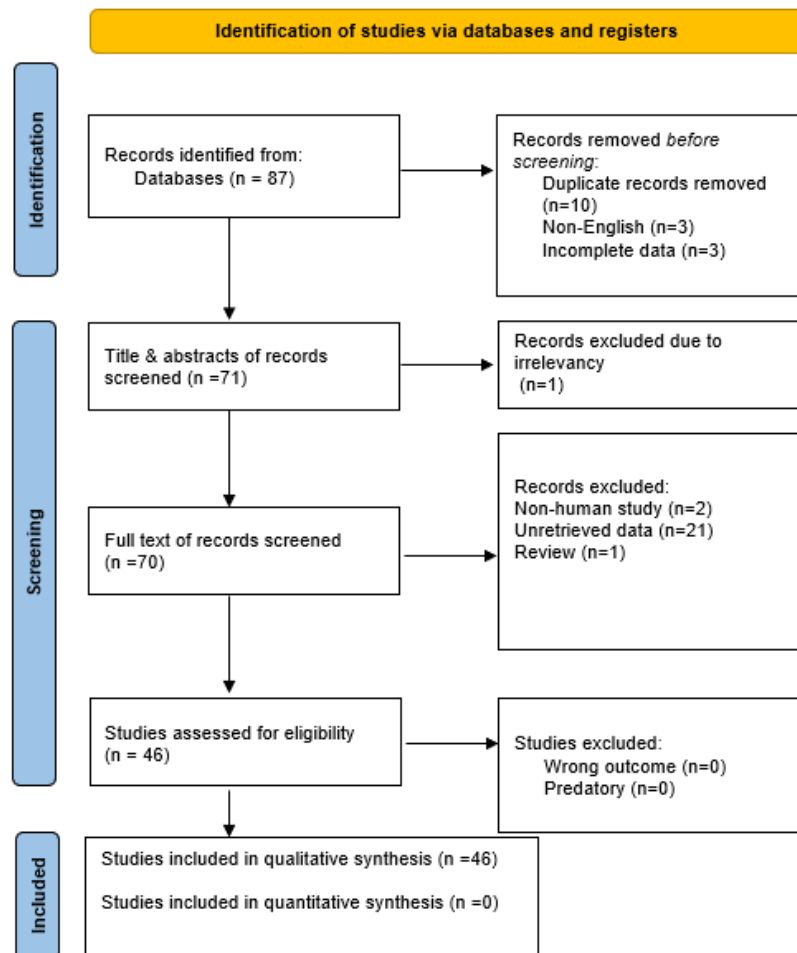


Figure 1. Study selection PRISMA flow chart.

approach was sputum culture, performed in 52 patients (69.3%). Other diagnostic methods included serology/titer in 16 patients (21.3%), bronchial washing culture in 13 patients (17.3%), histopathology in 13 patients (17.3%), bronchoalveolar lavage culture in 12 patients (16.0%), and tissue culture in nine patients (12.0%). Fifty patients (66.7%) had a primary PST, while 25 (33.3%) had multifocal disease. The most common species identified was *Sporothrix schenckii*, found in 58 patients (77.3%). *Sporothrix brasiliensis* was identified in 16 patients (21.3%) and *Sporothrix cyanescens* in one patient (1.3%). Treatment regimens varied among patients, with a combined conservative regimen being the most common, applied to 26 patients (34.7%). A single conservative regimen was used in 20 patients (26.7%), a single conservative regimen plus surgical intervention in 11 patients (14.6%), and a combined

#### 4. Discussion

Human sporotrichosis, caused by the thermally dimorphic fungi *Sporothrix schenckii* complex, exhibits various clinical manifestations. It was first discovered in 1898 in a patient with subcutaneous abscesses and initially placed in the genus *Sporotrichum*. However, taxonomic revisions in the 1960s reclassified it under the genus *Sporothrix*. *Sporothrix schenckii* is now understood to be a genetically diverse cryptic species complex that includes *S. globosa*, *S. brasiliensis*, *S. luriei*, *S. mexicana*, *S. pallida* (formerly *S. albicans*), and *S. schenckii sensu stricto*. All species, except *S. pallida*, are capable of causing disease in humans [49].

The fungus typically thrives in tropical and subtropical climates across the American continents (notably Brazil, Uruguay,

**Table 1.** The characteristic of studies and patients' demographics and clinical status.

Author, year [reference]	Country	Study design	Gender	Age (years)	Occupation	Lifestyle risk factor	Comorbidities and other health pattern	PMH of the disease	Immunity status
Fichman et al.* 2022 [1]	Brazil	Cohort	M	71	N/A	Smoker	COPD, Alcoholism	No	Immunocompromised
			M	63	N/A	Smoker	COPD, Alcoholism	No	Immunocompromised
			M	52	N/A	Smoker	HIV, Infection with <i>Klebsiella sp.</i>	No	Immunocompromised
			M	25	N/A	Smoker	HIV, TB, Alcoholism	No	Immunocompromised
			F	31	N/A	Smoker	HIV, Pulmonary sepsis, Kaposi sarcoma	No	Immunocompromised
			F	20	N/A	None	HIV	No	Immunocompromised
			M	44	N/A	Smoker	HIV, TB, Alcoholism	No	Immunocompromised
			M	26	N/A	Smoker	HIV, Alcoholism	No	Immunocompromised
			M	36	N/A	Smoker	HIV	No	Immunocompromised
			M	46	N/A	Smoker	HIV, Alcoholism	No	Immunocompromised
			M	18	N/A	None	Nocardiosis, Alcoholism	No	Immunocompromised
			M	35	N/A	Smoker	HIV, TB, Alcoholism	No	Immunocompromised
M	43	N/A	Smoker	HIV, TB, Alcoholism	No	Immunocompromised			
F	20	N/A	None	HIV, Pneumocystis pneumonia, Alcoholism	No	Immunocompromised			
Alves et al. 2020 [2]	Brazil	Case report	F	50	Salesman	Occupational exposure, Contact with dog and cat	Aspergillosis	No	Immunocompetent
Singhai et al. 2020 [8]	India	Case report	M	22	Farmer	Occupational exposure	Alcoholism	No	N/A
Farooqui et al. 2018 [9]	USA	Case report	M	44	Transporter of bird seed bags	Smoker	Infection with <i>streptococcus viridians</i> , Candida of neck abscess, Squamous cell carcinoma	Yes	N/A
Rojas et al. 2017 [6]	Argentina	Case report	F	65	N/A	Smoker	Arterial hypertension, Infection with <i>Klebsiella pneumoniae</i>	No	N/A
Bahr et al. 2015 [10]	USA	Case report	M	49	N/A	None	Pulmonary fibrosis, Infection with <i>Escherichia coli</i> , <i>Streptococcus viridans</i> , <i>Staphylococcus sp.</i> , <i>enterococcus sp.</i> and <i>Candida famata</i>	No	Immunocompromised
Aung et al. 2013 [4]	Australia	Case report	M	64	Gardner	Smoker, Occupational exposure	Emphysema, Rheumatoid arthritis, Influenza A, and Infection with <i>staphylococcus aureus</i> , <i>Achromobacter sp.</i>	Yes	N/A
			M	60	N/A	Smoker	Myocardial infarction, Emphysema	No	N/A
da Silva et al. 2013 [11]	Brazil	Case report	F	74	Gardner	Occupational exposure	COPD	No	N/A
Orofino-Costa et al. 2013 [12]	Brazil	Case report	M	32	N/A	Occupational exposure	Tobacco and alcohol abuse	No	N/A
Tiwari et al. 2012 [13]	USA	Case report	F	61	Gardner	Occupational exposure	Anal cancer, non-Hodgkin lymphoma	No	Immunocompromised
Zagurovskaya et al. 2010 [5]	USA	Case report	M	68	N/A	Smoker, Contact with old wooden materials	Coronary artery disease, Peripheral vascular disease, Dyslipidemia, Anxiety	No	N/A
Callens et al. 2005 [14]	USA	Case report	M	11	N/A	None	HIV, Infection with <i>Plasmodium sp.</i>	No	Immunocompromised
Mehta et al. 2004 [15]	USA	Case report	F	55	Florist and Hay rack builder	Occupational exposure	Asthma, Hypothyroidism, Nephrolithiasis, Inflammatory bowel disease	No	N/A
Zhou et al. 2003 [16]	USA	Case report	M	71	N/A	None	DM, COPD, Asthmatic bronchitis, Bronchiectasis	No	N/A

Table 1. Continued...

Byrd et al. 1998 [17]	USA	Case report	M	50	Landscaper	Occupational exposure, Smoker	COPD	No	N/A
Gori et al. 1997 [18]	Italy	Case report	M	37	N/A	None	HIV	No	Immunocompromised
Tambini et al. 1996 [19]	Italy	Case report	M	52	Farmer	Occupational exposure	Heart transplantation	No	Immunocompromised
Breeling et al. 1993 [20]	USA	Case report	F	62	N/A	Smoker	No	No	N/A
Padhye et al. 1992 [21]	India	Case report	F	43	N/A	None	Asthma, Infection with <i>Candida sp.</i>	No	N/A
Haponik et al. 1989 [22]	USA	Case report	M	57	Brickyard	Smoker, Environmental exposure	No	No	N/A
Fields et al. 1989 [23]	USA	Case report	M	47	N/A	Smoker	Alcohol and tobacco abuse	No	N/A
Velji et al. 1988 [24]	USA	Case report	M	79	Farmer	Occupational exposure	Alcohol abuse	No	N/A
Dall et al. 1987 [25]	USA	Case report	F	44	N/A	None	Pancreatitis, Alcohol abuse, pulmonary disease	No	N/A
			M	18	N/A	None	No	No	N/A
			M	50	N/A	Smoker	Bronchopneumonia, TB	No	N/A
Pluss et al. 1986 [26]	USA	Case series	M	64	Street cleaner	Smoker, Occupational exposure	COPD	No	N/A
			M	39	Army artillery sergeant	Smoker	Ethanol abuse	No	N/A
Pueringer et al. 1986 [27]	USA	Case report	M	23	N/A	None	DM, Alcohol abuse, Infection with <i>Streptococcus pneumoniae</i>	No	N/A
Matthews et al. 1982 [28]	South Africa	Case report	F	56	Gardner	Occupational exposure	No	No	N/A
			M	47	Construction worker	Occupational exposure	Alcoholism	No	N/A
Rohatgi 1980 [29]	USA	Case report	F	62	School teacher	None	Rheumatoid arthritis, Respiratory infection		N/A
			M	31	Fisherman	Smoker	No	No	N/A
			M	59	N/A	None	TB	No	N/A
Jung et al. 1978 [30]	USA	Case series	M	41	N/A	None	TB	No	N/A
			M	51	N/A	None	No	No	N/A
			M	42	N/A	None	Alcoholism	No	N/A
Lowenstein et al. 1978 [31]	USA	Case report	M	48	Gardner	Occupational exposure	Renal TB	No	N/A
Zvetina et al. 1978 [32]	USA	Case report	M	67	Farmer	Occupational exposure	No	No	N/A
Berson et al. 1977 [33]	South Africa	Case report	M	36	Gold miner	Occupational exposure	No	No	N/A
Michelson 1977 [34]	USA	Case report	M	38	Postal employee	None	No	No	N/A
Kinas et al. 1976 [35]	USA	Case report	M	48	Mounted policeman	Occupational exposure	Alcohol abuse, Infection with <i>E. coli</i> , pneumonia	No	N/A
			M	36	Truck driver	Contact with roses	Infection with <i>Actinomyces israelii</i>	No	N/A
Serstock et al. 1975 [36]	USA	Case report	M	77	N/A	Contact with roses	No	No	N/A
Evers et al. 1974 [37]	USA	Case report	M	37	Salesman	Smoker, Environmental exposure	No	No	N/A
Mohr et al. 1972 [38]	USA	Case report	M	56	Landscaper	Occupational exposure	DM	No	N/A
			F	44	Tavern operator	None	No	No	N/A
Smith et al. 1970 [39]	USA	Case report	M	51	N/A	None	No	No	N/A
	USA		M	38	N/A	None	Sarcoidosis	No	N/A

Table 1. Continued...

Author(s) [ref]	Country	Study Design	Sex	Age	Occupation	Occupational exposure	Comorbidity	PMH	Outcome
Baum et al. 1969 [40]		Case series	M	30	Produce handler	Occupational exposure	Hepatitis	No	N/A
			M	44	Greenhouse operator	Occupational exposure	TB	No	N/A
			M	34	Greenhouse operator and Produce handler	Occupational exposure	No	No	N/A
Kobayashi et al. 1969 [41]	USA	Case report	F	61	Florist	Occupational exposure	Peripheral vascular disease, Mumps, Infection with <i>Candida sp.</i>	Yes	N/A
McGavran et al. 1969 [42]	USA	Case report	M	59	Office worker	None	TB, histoplasmosis	No	N/A
Beland et al. 1968 [43]	Canada	Case report	M	49	N/A	None	Infection with <i>Klebsiella pneumoniae</i>	No	N/A
Trevathan et al. 1966 [44]	USA	Case report	M	40	Salesman	None	No	No	N/A
Siegrist et al. 1965 [45]	USA	Case report	M	43	Salesman	Smoker	Alcohol Abuse, Ulcerated stomach	No	N/A
Ridgeway et al. 1962 [46]	USA	Case report	M	35	N/A	None	Alcohol abuse, Malaria	No	N/A
			M	30	Truck driver	None	Alcohol abuse, Infection with <i>Candida sp.</i>	No	N/A
Scott et al. 1961 [47]	USA	Case report	M	26	X-ray technician	None	Alcoholism	No	N/A
			M	42	Florist	None	Syphilis	No	N/A
Post et al. 1958 [48]	USA	Case report	M	53	Farmer	Occupational exposure	No	No	N/A

M; male, F; female, N/A; non-available, COPD; chronic obstructive pulmonary disease, HIV; human immunodeficiency virus, TB; tuberculosis, DM; diabetes mellitus, PMH; past medical history.

\*The lifestyle risk factors for the cases are randomly provided in the table as the study did not report them per case.

Table 2. Summary of study affiliations and patients' demographics and clinical status.

Variables	Frequency / Percentage
<b>Country of study</b>	
USA	33 (71.7%)
Brazil	4 (8.7%)
India	2 (4.3%)
Italy	2 (4.3%)
South Africa	2 (4.3%)
Argentina	1 (2.2%)
Australia	1 (2.2%)
Canada	1 (2.2%)
<b>Patient demographics</b>	
Age range (median, mean $\pm$ SD), years	11 – 79 (44, 45.8 $\pm$ 15.17)
Gender	
Male	60 (80.0%)
Female	15 (20.0%)
<b>Lifestyle risk factor</b>	
None	27 (36.0%)
Smoker	26 (34.7%)
Occupational exposure	23 (30.7%)
Contact with roses/ wooden materials/ pets	4 (5.3%)
Environmental exposure	2 (2.7%)
<b>Comorbidities and other health pattern</b>	
Alcoholic	24 (32.0%)
Bacterial infection	22 (29.3%)
Respiratory & pulmonary diseases	18 (24%)
None	16 (21.3%)
HIV	13 (17.3%)

Other fungal infection	<b>6 (8.0%)</b>
Cancer	3 (4.0%)
Diabetes mellitus	3 (4.0%)
Others	14 (18.7%)
<b>Past medical history of the disease</b>	
Yes	3 (4.0%)
No	72 (96.0%)
<b>Immunity status</b>	
Immunocompromised	19 (25.3%)
Immunocompetent	1 (1.3%)
N/A	55 (73.3%)

Colombia, Peru, and Mexico), parts of Africa (especially sub-Saharan regions and South Africa), Asia (mainly Japan, India, and China), and Australia. Certain regions in South America, such as Abancay, are highly endemic areas, with sporotrichosis incidence rates reaching up to 60 cases per 100,000 annually [49]. However, PST's prevalence and incidence rates are not well-documented, even in hyperendemic regions. The epidemiology of reported PST cases is heavily influenced by publication bias, with nearly 90% of cases originating from the USA. In endemic regions, many PST cases are probably underreported or misdiagnosed [4]. During the first large sporotrichosis epidemic, which occurred in the mines of Transvaal, South Africa, 3,000 cases of the cutaneous form were reported, with no diagnoses of PST [50]. On the contrary, in 2019, Falcão et al. reviewed the Brazilian Unified National Health System and found that PST was the most common clinical form of sporotrichosis. This type accounted for at least 220 hospitalizations, representing 35.9% of all sporotrichosis



**Table 3.** Presentation and diagnosis of sporotrichosis.

Author, year [reference]	Presentation	Imaging findings	Diagnostic approach	Disease focality	Species
Fichman et al.* 2022 [1]	Malaise, weight loss, fever, cough, hemoptysis, dyspnea	Reticulonodular infiltration, cavitory lesion, and fibrosis	Sputum, BAL culture	Primary	<i>S. brasiliensis</i>
	Malaise, weight loss, fever, cough, hemoptysis	Cavitory lesions, fibrosis, lymphadenopathy	Sputum, BAL culture	Multifocal	<i>S. brasiliensis</i>
	Malaise, weight loss, fever, cough	Unilobular nodule without cavitation	BAL culture	Multifocal	<i>S. brasiliensis</i>
	Malaise, weight loss, fever, cough	Unilobular multiple nodules without cavitation	Sputum, BAL culture	Multifocal	<i>S. brasiliensis</i>
	Malaise, weight loss, fever, cough	N/A	Sputum culture	Multifocal	<i>S. brasiliensis</i>
	Malaise, weight loss, fever, cough	Multiple bilateral pulmonary nodules without cavitation	Sputum culture	Multifocal	<i>S. brasiliensis</i>
	Malaise, weight loss, fever, cough	Pleural effusion	Sputum culture	Multifocal	<i>S. brasiliensis</i>
	Malaise, weight loss, fever, cough	N/A	Sputum culture	Multifocal	<i>S. brasiliensis</i>
	Malaise, weight loss, fever, cough	N/A	Sputum culture	Multifocal	<i>S. brasiliensis</i>
	Malaise, weight loss, fever	N/A	Sputum culture	Multifocal	<i>S. brasiliensis</i>
	Malaise, weight loss, fever	N/A	Sputum culture	Multifocal	<i>S. brasiliensis</i>
	Malaise, weight loss	N/A	Sputum culture	Multifocal	<i>S. brasiliensis</i>
	Malaise	Reticulonodular infiltration, calcified nodules, fibrosis and cavitation	Sputum culture	Multifocal	<i>S. brasiliensis</i>
	Malaise	Reticulonodular infiltration, consolidation	Sputum culture	Multifocal	<i>S. brasiliensis</i>
Alves et al. 2020 [2]	Snoring, cough, hyaline expectoration, dyspnea, weight loss	Multiple bilateral pulmonary nodules	CT and BAL Culture	Primary	<i>S. brasiliensis</i>
Singhai et al. 2020 [8]	Cough, dyspnea, fever	Cavitory lesion	Sputum culture	Primary	<i>S. schenckii</i>
Farooqui et al. 2018 [9]	Dysphagia, hemoptysis	Retropharyngeal mass, multiple pulmonary cavitations, and nodules	BAL culture, lung tissue biopsy	Primary	<i>S. schenckii</i>
Rojas et al. 2017 [6]	Fever, odynophagia, cough, dyspnea, septic shock, multiorgan failure	Cavitory lesion	BAL culture	Primary	<i>S. schenckii</i>
Bahr et al. 2015 [10]	Admitted for lung transplantation	N/A	BAL culture	Primary	<i>S. schenckii</i>
Aung et al. 2013 [4]	Cough, fever, hemoptysis	Cavitory lesions	BAL, sputum and lung tissue culture	Primary	<i>S. schenckii</i>
	Emphysema, cough, respiratory failure	Pleural scarring with a large, thick-walled cavity	Sputum culture	Primary	<i>S. schenckii</i>
da Silva et al. 2013 [11]	Dyspnea, cough, fever, malaise	Ground-glass attenuation with traction bronchiectasis	Lung tissue culture	Primary	<i>S. schenckii</i>
Orofino-Costa et al. 2013 [12]	Cough, fever, asthenia, diarrhea, myalgia, weight loss, cutaneous lesions	Cavitory lesions	Serology, Skin biopsy, sputum culture	Multifocal	<i>S. brasiliensis</i>
Tiwari et al. 2012 [13]	Asymptomatic	Multiple lung nodules and cavitation	Bronchial washing	Primary	<i>S. schenckii</i>
Zagurovskaya et al. 2010 [5]	Hemoptysis, cough	Cavitory lesion	BAL culture	Primary	<i>S. schenckii</i>
Callens et al. 2005 [14]	Cough, oral lesions, conjunctival pallor, hypochromic eruptions, fever, diarrhea, vomiting, dyspnea, rhinorrhea, hemoptysis, night sweat	N/A	Sputum culture	Multifocal	<i>S. schenckii</i>
	Fever, sweats, nasal congestion, cough, dyspnea	Lung infiltration, nodules, and bronchiectasis changes	BAL culture	Primary	<i>S. schenckii</i>
Zhou et al. 2003 [16]	Cough, sore throat, hoarseness, yellowish sputum	Lung infiltration	Vocal cord biopsy, transbronchial biopsy, sputum culture, BAL culture, bronchial wash	Multifocal	<i>S. schenckii</i>
Byrd et al. 1998 [17]	Weight loss, hemoptysis, lung cavity on imaging	Cavitory lesions	Titer	Primary	<i>S. schenckii</i>
Gori et al. 1997 [18]	Cough, dyspnea	N/A	Sputum culture	Primary	<i>S. schenckii</i>
Tambini et al. 1996 [19]	Asymptomatic	Cavitory lesion	Culture biopsy	Primary	<i>S. cyanescens</i>
Breeling et al. 1993 [20]	Hemoptysis, dyspnea, weight loss, fever, cough	Cavitory lesions	Bronchoscopy, sputum culture	Primary	<i>S. schenckii</i>
Padhye et al. 1992 [21]	Acute respiratory distress, fever, cough	Lung infiltration and cavitation	HPE and periodic acid-Schiff staining	Primary	<i>S. schenckii</i>

Table 3. Continued...

Haponik et al. 1989 [22]	Hemoptysis, shock, acute respiratory distress, bloody expectoration	Cavitary lesions	Sputum culture, Titer	Primary	<i>S. schenckii</i>		
Fields et al. 1989 [23]	Upper and lower extremities pruritic erythematous lesions, cough, fever, chills, malaise, hemoptysis, weight loss	Pleural effusion, lung infiltration	Titer and pleural fluid and sputum cultures	Multifocal	<i>S. schenckii</i>		
Velji et al. 1988 [24]	Skin lesions, weight loss	Lung infiltration	Tissue, sputum and skin aspiration culture, titer	Multifocal	<i>S. schenckii</i>		
Dall et al. 1987 [25]	Cough, weight loss, night sweat, fatigue	Interstitial markings, Cystic changes, cavitary lesion	Bronchoscopy, Open biopsy, lung tissue and bronchial washing culture	Primary	<i>S. schenckii</i>		
Pluss et al. 1986 [26]	Arthralgia, skin lesions, fever, cough, chest pain, draining cystic lesion of the eyelid	Bilateral hilar and paratracheal adenopathy, trachea compression, bronchi masses	Skin and bronchial biopsy	Multifocal	<i>S. schenckii</i>		
	Hemorrhagic gastritis due to alcoholism	Lung infiltration	Bronchial wash and brushing Culture	Primary	<i>S. schenckii</i>		
	Myocardial infarction	Fibrocavitary disease, lung infiltration	Sputum culture, bronchial washing, titers	Primary	<i>S. schenckii</i>		
Pueringer et al. 1986 [27]	Cough, bloody sputum, fever, weight loss	Extensive consolidation	Gomori's methenamine silver staining, bronchial washing, lung biopsy	Primary	<i>S. schenckii</i>		
			Sputum culture, bronchial brushing culture, titer	Primary	<i>S. schenckii</i>		
			Skin biopsy	Multifocal	<i>S. schenckii</i>		
Matthews et al. 1982 [28]	Skin lesion, pyrexia, anorexia, weight loss	Diffuse soft nodular infiltrate of both lungs without cavitation	Skin biopsy	Multifocal	<i>S. schenckii</i>		
Rohatgi 1980 [29]	Pleuritic chest pain, cough, fever, anorexia, dyspnea, weight loss	Segmental consolidation	Skin biopsy, bronchial wash, and sputum culture	Multifocal	<i>S. schenckii</i>		
			Sputum culture, bronchial washing, titer	Primary	<i>S. schenckii</i>		
			Direct fluorescent antibody test	Primary	<i>S. schenckii</i>		
Jung et al. 1978 [30]	Malaise, fatigue, anorexia, weight loss, cough, fever, pleuritic pain	Segmental consolidation	Sputum culture, bronchial washing, titer	Primary	<i>S. schenckii</i>		
			Sharply defined nodules without cavitation	Primary	<i>S. schenckii</i>		
			Cough, fever, malaise, chest pain, hemoptysis	Cavitary lesion	Sputum culture	Primary	<i>S. schenckii</i>
Lowenstein et al. 1978 [31]	Hemoptysis, cough, malaise, fever, weight loss	Thickened pleura, cavitary lesion, contracted hemithorax	Sputum culture	Primary	<i>S. schenckii</i>		
			Chest pain, cough, dyspnea	Cavitary disease, lung infiltration	Sputum culture	Primary	<i>S. schenckii</i>
			Abnormal X-ray finding	Cavitary disease, lung infiltration	Sputum culture, brushing culture, titer, culture specimen	Primary	<i>S. schenckii</i>
Zvetina et al. 1978 [32]	N/A	Apical bullae	Sputum culture	Primary	<i>S. schenckii</i>		
Berson et al. 1977 [33]	Anorexia, weight loss, fatigue	Lung infiltration, cavitation	Sputum culture, titer, HPE	Primary	<i>S. schenckii</i>		
Michelson 1977 [34]	Debility, parotitis, bleeding tongue	N/A	Post-mortem HPE	Primary	<i>S. schenckii</i>		
			Bronchial washing culture, lung biopsy, periodic acid-Schiff staining	Primary	<i>S. schenckii</i>		
Kinas et al. 1976 [35]	Fatigue, weight loss, fever	Lung infiltration	Bronchial washing culture, lung biopsy, periodic acid-Schiff staining	Primary	<i>S. schenckii</i>		
Serstock et al. 1975 [36]	Mucoid purulent expectoration, weakness, weight loss, dyspnea	Small density and infiltration	Sputum culture, serology	Primary	<i>S. schenckii</i>		
			Sputum culture, titer, skin test, specimen culture, animal inoculation	Multifocal	<i>S. schenckii</i>		
Evers et al. 1974 [37]	Chest pain, cough	Lung fibrotic infiltration and cavitation	Skin aspirate culture, skin test, animal inoculation	Multifocal	<i>S. schenckii</i>		
			Bronchial wash and sputum culture	Primary	<i>S. schenckii</i>		
Mohr et al. 1972 [38]	Chills, fever, fatigue, weight loss	Small infiltration	Bronchial wash and sputum culture	Primary	<i>S. schenckii</i>		
			Multiple cavitary lesions and infiltration	Sputum culture	Primary	<i>S. schenckii</i>	
Smith et al. 1970 [39]	Cough, fever, malaise	Lung infiltrative cavitation	Sputum culture	Primary	<i>S. schenckii</i>		
			Fibronodular infiltrates and apical cavities	Sputum culture	Primary	<i>S. schenckii</i>	
Baum et al. 1969 [40]	Cough, fever, malaise	Lung infiltrative cavitation	HPE, Sputum culture, titer	Primary	<i>S. schenckii</i>		
			Bilateral linear densities	Sputum culture	Multifocal	<i>S. schenckii</i>	
			Cavitary lesions	Sputum culture	Primary	<i>S. schenckii</i>	
Kobayashi et al. 1969 [41]	N/A	Cavitary lesions	Sputum culture	Primary	<i>S. schenckii</i>		
			Cavitary lesions	Sputum culture	Primary	<i>S. schenckii</i>	
McGavran et al. 1969 [42]	Skin lesion	Cavitary lesions	Sputum culture	Primary	<i>S. schenckii</i>		
			Recurrent leg ulcers, cutaneous lesions, night sweats, fatigue, cough, weight loss	Fibrotic, contracted infiltration and cavitation of the lungs	Sputum culture, Biopsy	Multifocal	<i>S. schenckii</i>
McGavran et al. 1969 [42]	Cough, fever, weight loss	Bilateral infiltration of the lungs	Sputum culture	Primary	<i>S. schenckii</i>		



**Table 3.** Continued...

Beland et al. 1968 [43]	Cough, dyspnea	Cavitary lesions	Specimen culture, animal inoculation	Primary	<i>S. schenckii</i>
Trevathan et al. 1966 [44]	Malaise, weight loss, cough, mucoid sputum, hemoptysis	Cavitary lesion	Bronchial washing and sputum culture	Primary	<i>S. schenckii</i>
Siegrist et al. 1965 [45]	Syncope, cough, night sweats, fever, dyspnea, hemoptysis, anorexia, weight loss	Lung fibrotic infiltration with cavitation	Sputum culture, animal inoculation	Primary	<i>S. schenckii</i>
Ridgeway et al. 1962 [46]	Fever, pleuritic pain, cough, hemoptysis, weight loss	Irregular soft density (cavitation)	Sputum culture, Specimen culture	Primary	<i>S. schenckii</i>
	Epigastric pain, vomiting, cough, chest pain	Cavitary lesion	Bronchial wash culture, Titer, periodic acid-Schiff staining	Primary	<i>S. schenckii</i>
Scott et al. 1961 [47]	Fever, night sweats, weight loss, cough, hemoptysis, hoarseness, vomiting, diarrhea, hepatomegaly, jaundice	Lung infiltration and cavitation	Sputum culture, gastric washing, titer	Primary	<i>S. schenckii</i>
	Asymptomatic	Cavitary lesion, fibrotic infiltration	Sputum culture, gastric washing, periodic acid-Schiff	Primary	<i>S. schenckii</i>
Post et al. 1958 [48]	Dyspnea, cough	Fibrocavitary disease	Sputum culture, titer, bronchial washing culture	Primary	<i>S. schenckii</i>

N/A; non-available, BAL; Bronchoalveolar lavage, CT; computed tomography, HPE; histopathology examination

\* The symptoms for that study, except malaise, are randomly provided in the table as the study did not report them per case.

**Table 4.** Treatment and outcome of the patients with sporotrichosis.

Author, year [reference]	Treatment	Complications after treatment	ICU	Outcome	Recurrence
	Itraconazole, Posaconazole	None	No	Survived	No
	Itraconazole, Posaconazole, Amphotericin B	None	No	Survived	No
	Itraconazole, Amphotericin B	None	No	Survived	No
	Itraconazole, Posaconazole, Amphotericin B, Terbinafine	None	No	Died	-----
	Itraconazole, Amphotericin B	None	No	Survived	No
	Itraconazole, Posaconazole, Amphotericin B, Terbinafine	None	No	Died	-----
Fichman et al. 2022 [1]	Itraconazole, Amphotericin B	None	No	Died	-----
	Itraconazole, Amphotericin B	None	No	Died	-----
	Itraconazole, Posaconazole, Amphotericin B	None	No	N/A	N/A
	Itraconazole, Amphotericin B	None	No	Survived	No
	Itraconazole, Posaconazole, Amphotericin B	None	No	Survived	No
	Itraconazole, Amphotericin B	None	No	Died	-----
	Itraconazole, Posaconazole, Amphotericin B, Terbinafine	None	No	Died	-----
	Itraconazole, Posaconazole, Amphotericin B	None	No	Survived	No
Alves et al. 2020 [2]	Amphotericin B, Itraconazole	Acute respiratory failure, Acute renal insufficiency, and Injury, Septic shock	Yes	Died	-----
Singhai et al. 2020 [8]	Itraconazole	None	No	Survived	No
Farooqui et al. 2018 [9]	Itraconazole, Pneumonectomy	Progressive disease	No	Survived	N/A
Rojas et al. 2017 [6]	Amphotericin B, Itraconazole	None	Yes	N/A	N/A
Bahr et al. 2015 [10]	Amphotericin B, Itraconazole	None	Yes	Survived	No
Aung et al. 2013 [4]	Itraconazole, Voriconazole, Lobectomy	Hemoptysis	Yes	Survived	No
	Itraconazole, Intravenous antibiotics, Bronchodilators, Steroids	None	No	Died	-----
da Silva et al. 2013 [11]	Wedge resection, Itraconazole	None	No	Survived	No
Orofino-Costa et al. 2013 [12]	Amphotericin B, Itraconazole	None	No	Survived	N/A
Tiwari et al. 2012 [13]	Itraconazole	None	No	Survived	No
Zagurovskaya et al. 2010 [5]	Itraconazole	None	No	Survived	No
Callens et al. 2005 [14]	Fluconazole	None	No	Survived	No
Mehta et al. 2004 [15]	N/A	N/A	No	N/A	N/A
Zhou et al. 2003 [16]	Itraconazole	None	No	Survived	No
Byrd et al. 1998 [17]	Itraconazole	None	No	Survived	No
Gori et al. 1997 [18]	No	N/A	No	N/A	N/A
Tambini et al. 1996 [19]	Amphotericin B	None	No	Survived	No
Breeling et al. 1993 [20]	Amphotericin B, Potassium Iodide, Ketoconazole, Itraconazole	Hypothyroid	No	Survived	No
Padhye et al. 1992 [21]	The case died before diagnosis	N/A	Yes	Died	-----
Haponik et al. 1989 [22]	Amphotericin B, Pneumonectomy	Respiratory failure, Pulmonary hypertension, Pneumonia	No	Died	-----
Fields et al. 1989 [23]	Potassium Iodide, Ketoconazole	None	No	N/A	N/A
Velji et al. 1988 [24]	Amphotericin B	None	No	Survived	No
Dall et al. 1987 [25]	Amphotericin B, Ketoconazole, Miconazole, Flucytosine, Pneumonectomy	None	No	Survived	No

Table 4. Continued...

	Amphotericin B	None	No	Survived	No
	Potassium Iodides	None	No	Survived	No
Pluss et al. 1986 [26]	Amphotericin B, Miconazole, Ketoconazole	Renal insufficiency due to Amphotericin	No	Survived	Yes
	Lobectomy, Ketoconazole, Upper lobe cystectomy,	None	No	Survived	Yes
Pueringer et al. 1986 [27]	Amphotericin B	None	No	Survived	No
Matthews et al. 1982 [28]	Potassium Iodide, Amphotericin B	Urea and Creatinine rise	No	Survived	Yes
Rohatgi 1980 [29]	Amphotericin B	None	No	Survived	No
	Potassium Iodide	None	No	Survived	N/A
	No	N/A	No	N/A	N/A
	Amphotericin B, Potassium Iodide, Staged thoracoplasty	None	No	N/A	N/A
Jung et al. 1978 [30]	Amphotericin B	None	No	Survived	No
	Amphotericin B	None	No	Survived	No
	Amphotericin B, Lobectomy	Air leak due to lobectomy	No	Survived	No
Lowenstein et al. 1978 [31]	No	N/A	No	Survived	N/A
Zvetina et al. 1978 [32]	Lobectomy, Potassium Iodide	None	No	Survived	No
Berson et al. 1977 [33]	No	N/A	No	Died	-----
Michelson 1977 [34]	Thoracotomy, Potassium Iodide	None	No	Survived	No
Kinas et al. 1976 [35]	Amphotericin B	Toxic reaction	No	Died	-----
Serstock et al. 1975 [36]	Amphotericin B, Segmentectomy	None	No	Survived	No
	Amphotericin B, Segmentectomy	None	No	Survived	N/A
Evers et al. 1974 [37]	Potassium Iodide	None	No	Survived	No
Mohr et al. 1972 [38]	Potassium Iodide, Tetracycline, Lobectomy	None	No	Survived	No
	Amphotericin B	Aspergillosis (not related to treatment)	No	Survived	No
Smith et al. 1970 [39]	Segmentectomy, Amphotericin B, Potassium Iodide, Hydroxystilbamadine	None	No	Died	-----
	Amphotericin B	None	No	Survived	N/A
Baum et al. 1969 [40]	Amphotericin B, Iodides, Surgery	None	No	Survived	No
	Amphotericin B, Iodides, Surgery	None	No	Survived	N/A
	Amphotericin B, Iodides, Surgery	None	No	Survived	No
Kobayashi et al. 1969 [41]	Potassium Iodide, Amphotericin B	Hypotension	No	N/A	N/A
McGavran et al. 1969 [42]	Potassium Iodide, Amphotericin B, Pneumonectomy	Persistent symptoms	No	Died	-----
Beland et al. 1968 [43]	Lobectomy	None	No	Survived	No
Trevathan et al. 1966 [44]	Potassium Iodide, Griseofulvin	None	No	Survived	No
Siegrist et al. 1965 [45]	Potassium Iodide, lobectomy	None	No	Survived	No
Ridgeway et al. 1962 [46]	Lobectomy, Potassium Iodide	None	No	Survived	No
	Potassium Iodide, Thoracotomy and Segmentectomy, Amphotericin B	Severe conjunctivitis, Rhinitis, Atelectasis	No	Survived	N/A
Scott et al. 1961 [47]	Potassium Iodide	None	No	Died	-----
	Potassium Iodide, Segmentectomy	None	No	Survived	N/A
Post et al. 1958 [48]	Potassium Iodide, Dihydroxystilbamadine, Amphotericin B	Side reaction to Dihydroxystilbamadine	No	Survived	N/A

cases registered in hospitals from 1998 to 2015 [51]. Another study identified 1,322 cases of sporotrichosis in a large commercial health insurance database in the USA from 2012 to 2018. Among the cases where sporotrichosis was specified, lymphocutaneous was the most prevalent, with 68 cases, followed by PST, which accounted for 27 cases [52]. In the current systematic review of 46 studies, most (71.7%) were from the USA, followed by Brazil (8.7%), supporting the assumption that many PST cases may be misdiagnosed or overlooked in endemic regions. The infected species were *S. schenckii* in 58 cases (77.3%), *S. brasiliensis* in 16 cases (21.3%), and *S. cyanescens* in one case (1.3%).

Sporotrichosis presents in two clinical patterns: primary, a unifocal disease caused by direct inhalation of the fungus, and multifocal sporotrichosis, which can occur through direct inhalation of conidia followed by dissemination or, more commonly, via hematogenous or lymphatic spread from a distant site, often due to immunosuppression [1]. Due to its rarity, PST has traditionally been classified under "extracutaneous manifestations" of sporotrichosis. However,

this classification is misleading, as most cases of PST do not exhibit cutaneous symptoms [49]. A systematic review of 86 cases of PST reported that 64 cases (74.4%) were of the primary pulmonary form [4]. In line with the previous study, 66.7% of the cases identified in the present study were primary PST. This finding further supports the view that PST should not be regarded merely as an extracutaneous manifestation of sporotrichosis but as an independent entity.

It has been reported that over 80% of the cases are males, and the mean age of presentation is between 40 and 50 years [49]. The commonly suggested risk factors for primary PST include middle age, male gender, smoking, chronic corticosteroid use, chronic obstructive pulmonary disease, alcoholism, and immunosuppressive diseases like HIV [4]. Chronic alcohol abuse leads to lymphopenia and persistent activation of the T cell pool, which can impair T cells' ability to proliferate and respond to pathogens. This condition disrupts the balance between T-helper (Th)1 and Th2 responses [1]. A study conducted by Fichman et al. observed that most cases were males of low educational and economic backgrounds.

**Table 5.** Summary of disease presentation, diagnosis and treatment.

Variables	Frequency / Percentage
<b>Symptoms/presentation*</b>	
Cough	46 (61.3%)
Fever	36 (48.0%)
Weight loss	34 (45.3%)
Malaise	30 (40.0%)
Hemoptysis	17 (22.7%)
Dyspnea	15 (20.0%)
Cutaneous lesions	10 (13.3%)
Chest pain	10 (13.3%)
Abnormal expectoration/sputum	6 (8.0%)
Night sweats	6 (8.0%)
Anorexia	5 (6.7%)
Others	47 (62.7%)
N/A	4 (5.3%)
<b>Common imaging findings*</b>	
Cavitary lesion	40 (53.3%)
Lung Infiltration	26 (34.7%)
Pulmonary nodule	10 (13.3%)
Fibrosis	7 (9.3%)
Consolidation	4 (5.3%)
<b>Common diagnostic approaches*</b>	
Sputum culture	52 (69.3%)
Serology/Titer	16 (21.3%)
Bronchial washing culture	13 (17.3%)
Histopathology	13 (17.3%)
BAL culture	12 (16.0%)
Tissue culture	9 (12.0%)
<b>Disease focality</b>	
Primary	50 (66.7%)
Multifocal	25 (33.3%)
<b>Species</b>	
<i>S. schenckii</i>	58 (77.3%)
<i>S. brasiliensis</i>	16 (21.3%)
<i>S. cyanescens</i>	1 (1.3%)
<b>Common treatment regimen</b>	
Combined conservative regimen	26 (34.7%)
Single conservative regimen	20 (26.7%)
Single conservative regimen + surgical intervention	11 (14.6%)
Combined conservative regimen + surgical intervention	11 (14.6%)
Surgical intervention alone	1 (1.3%)
No treatment/ N/A	6 (8.0%)
<b>ICU admission</b>	
Yes	5 (6.7%)
No	70 (93.3%)
<b>Outcome</b>	
Survived	52 (69.3%)
Died	15 (20.0%)
N/A	8 (10.7%)
<b>Recurrence among survived cases</b>	
	3 (5.8%)

N/A; non-available, BAL; Bronchoalveolar lavage, ICU; intensive care unit

\* For each case, multiple options may be present.

Predominantly, the patients exhibited multifocal disease with widespread skin lesions, and most (78.6%) were HIV-positive. They highlighted the crucial role of CD4+ T cells in controlling sporotrichosis, noting that these cells are also the primary target of HIV infection [1]. Nearly 50% of PST cases, whether in the primary or disseminated form, have identifiable occupational or environmental exposures to the fungus. These exposures include contact with plant materials, animals or animal products, and soil, particularly in bricklaying, gardening, or horticulture. In addition, heavy alcohol use has been noted in nearly 40% of reported cases. Patients with multifocal disseminated disease are more commonly immunocompromised (36.4%) than primary form (3.1%). Other associated immunosuppressive conditions include diabetes mellitus, chronic liver disease, malignancy, and autoimmune/connective tissue disorders, each occurring in less than 10% of cases. Additionally, about 25% of all cases have preexisting airway conditions such as COPD, asthma, and bronchiectasis [49]. Consistent with the literature, in this study, 80% of the cases were male, with a mean age of 45.8 years. In total, 34.7% were smokers, 32% were alcoholics, 30.7% had occupational exposure, 24% had respiratory or pulmonary disease, and 17.3% had HIV infection. Only four cases (5.3%) had contact with pets, roses, or other wooden materials, and two (2.7%) had environmental exposure. There were three cases (4%) with cancer and three with diabetes mellitus (4%). Only 19 cases (25.3%) were reported to be immunocompromised. These results indicate that the coexistence of multiple factors may be required to develop the disease.

Due to its nonspecific clinical presentation, particularly in cases of primary PST, the disease may be underestimated and misdiagnosed as other pulmonary infections, such as bacterial pneumonia and tuberculosis [1]. Up to 14% of primary PST cases are asymptomatic. When symptoms are present, the most common include cough, sputum production, and dyspnea in both primary pulmonary and multifocal disseminated forms. Constitutional symptoms such as fever, anorexia, and weight loss are prevalent in over 50% of patients, likely due to elevated levels of inflammatory cytokines such as tumor necrosis factors and interferons. Hemoptysis occurs significantly more frequently in primary PST than in multifocal disseminated disease, with rates of 42.2% and 9.1%, respectively. Coinfection with various bacteria (such as *S. pneumoniae*, *Klebsiella* species, *P. aeruginosa*, *Proteus* species, *S. aureus*, *A. israelii*, *M. tuberculosis*, and *M. avium complex*) and fungi (such as *Aspergillus* species, *Candida* species, and *Pneumocystis jirovecii*) has also been previously documented [49]. In the present study, coughing was the most common presentation (61.3%), followed by fever (48%), weight loss (45.3%), and malaise (40%). Hemoptysis was observed in 17 cases (22.7%), of which 14 (82.4%) were associated with primary disease, consistent with findings from the previous study. Twenty-two cases (29.3%) had bacterial coinfection, and six cases (8%) had fungal co-infection. Regarding bacterial coinfections, ten cases were infected with *M. tuberculosis*, three with *Streptococcus* species, three with *Klebsiella* species, two with *Staphylococcus* species, two with *E. coli*, and one each with *Actinomyces israelii*, *Pneumocystis jirovecii*, *Nocardia* species, *Enterococcus* species, and *Achromobacter* species. Among fungal coinfections, five cases involved *Candida* species, and one involved aspergillosis.

Pulmonary manifestations of *S. schenckii* are identifiable on chest X-rays or computed tomography scans. Comstock and Wolson were the first to recognize two distinct radiological patterns in pulmonary sporotrichosis: cavitary and noncavitary. These patterns are determined by whether the infection is confined to the lungs [53]. A systematic review conducted in 2013 revealed that most primary PST cases (77%) exhibited a cavitary pattern, whereas fewer than 10% of patients with multifocal disease showed cavities. Interestingly, 20% to 25% of patients with primary PST presented with noncavitary disease characterized by radiological findings such as reticulonodular infiltrates, consolidation, or fibrosis alone [4]. The most common imaging finding among reviewed cases was cavitary lesion (53.3%), followed by lung infiltration (34.7%). Of the 40 cases with cavitary lesions, 35 (87.5%) had primary PST.

The definitive diagnosis requires a fungal culture. Histopathological examination is not considered the most effective diagnostic method, as identifying the fungus in histological sections can be challenging [11]. In primary PST, the diagnosis is confirmed through the culture of sputum and bronchoscopic specimens. In contrast, in multifocal sporotrichosis, tissue samples from the skin and joints are typically used for diagnosis [9]. Among the reviewed cases, the

## 5. Conclusion

The coexistence of multiple risk factors, except only exposure to the fungus, may trigger the disease, including smoking, alcohol abuse, immunocompromised status, infection, malignancy, and other pulmonary diseases. Its low incidence in endemic areas suggests the potential for missed or misdiagnosed cases. Treatment approaches can include a combined conservative regimen or in combination with surgery. The survival rate can reach 69.3%; however, the mortality rate is significant at 20% and should not be overlooked.

## Declarations

**Conflicts of interest:** The author(s) have no conflicts of interest to disclose.

**Ethical approval:** Not applicable, as systematic reviews do not require ethical approval.

**Patient consent** (participation and publication): Not applicable.

**Funding:** The present study received no financial support.

**Acknowledgements:** None to be declared.

**Authors' contributions:** FHK, BAA, and MNH collected data. KAA designed the study. FHF performed the data analysis. HOB, YMM, and SHK prepared the manuscript. HKA, HMA, BJHA, HSM, FA and TMM critically revised the manuscript. FHK and HOA confirmed the authenticity of the data. All authors approved the final version of the manuscript.

**Data availability statement:** Note applicable.

primary diagnostic approach was sputum culture (69.3%), followed by serology or titer (21.3%).

Treating both forms is challenging. For mild to moderate lung disease, the oral administration of itraconazole at 200 mg twice

daily for 12 months is recommended. In severe cases, a lipid formulation of amphotericin B (lipid complex or liposomal) at 3–5 mg/kg is advised until a positive response is observed. Afterward, the treatment can be switched to itraconazole 200 mg twice daily for 12 months. For localized pulmonary disease, a combination of surgery and amphotericin B therapy is suggested [1]. The present review found that 34.7% of cases were managed with a combined conservative regimen and 26.7% with a single conservative regimen. Conservative treatment combined with surgery was employed in 22 cases (29.2%). Only one case (1.3%) was treated with surgery alone. The severity of the disease necessitated ICU admission in five cases (6.7%). The survival rate was 69.3%, and recurrence occurred in three cases (5.8%). The limitations of this study stem from the nature of the included studies, as most were case reports, which may introduce bias into the findings. Additionally, the lack of experimental studies on the subject limited the potential for more comprehensive findings.

## References

- Fichman V, Mota-Damasceno CG, Procópio-Azevedo AC, Almeida-Silva F, de Macedo PM, Medeiros DM, et al. Pulmonary sporotrichosis caused by *Sporothrix brasiliensis*: a 22-year, single-center, retrospective cohort study. *Journal of Fungi*. 2022;8(5):536. doi:10.3390/jof8050536.
- do Monte Alves M, Pipolo Milan E, da Silva-Rocha WP, Soares de Sena da Costa A, Araújo Maciel B, Cavalcante Vale PH, et al. Fatal pulmonary sporotrichosis is caused by *Sporothrix brasiliensis* in northeast Brazil. *PLoS Neglected Tropical Diseases*. 2020;14(5):e0008141. doi:10.1371/journal.pntd.0008141.
- Orofino-Costa R, Macedo PM, Rodrigues AM, Bernardes-Engemann AR. Sporotrichosis: an update on epidemiology, etiopathogenesis, laboratory and clinical therapeutics. *Anais brasileiros de dermatologia*. 2017;92(5):606-20. doi:10.1590/abd1806-4841.2017279.
- Aung AK, Teh BM, McGrath C, Thompson PJ. Pulmonary sporotrichosis: case series and systematic analysis of literature on clinico-radiological patterns and management outcomes. *Medical mycology*. 2013;51(5):534-44. doi:10.3109/13693786.2012.751643.
- Zagurovskaya M, Alexander M, Koselka H. Primary pulmonary sporotrichosis in an immunocompetent host. *American Journal of Case Reports*. 2010;11:174-8. doi:N/A
- Rojas FD, Fernández MS, Lucchelli JM, Lombardi D, Malet J, Vetrivano ME, et al. Cavitary pulmonary sporotrichosis: case report and literature review. *Mycopathologia*. 2017;182:1119-23. doi:10.1007/s11046-017-0197-6.
- Mohammed, K. K., Hama, J. I., & Kakamad, F. H. (2024). Beyond Beall's list: The need for contemporary evaluation tools in predatory publishing research. *Learned Publishing*, 37(2), 157-158. doi:10.1002/leap.1602
- Singhai M, Rawat V, Verma P, Jha PK, Shree D, Goyal R. Primary pulmonary sporotrichosis in a sub-Himalayan patient. *Journal of laboratory physicians*. 2012;4(01): 48-9. doi:10.4103/0974-2727.98674.
- Farooqui SM, Youness H. The Infection Returns: A case of pulmonary sporotrichosis relapse after chemotherapy. *Case Reports in Medicine*. 2018;2018(1):1384029. doi:10.1155/2018/1384029.
- Bahr NC, Janssen K, Billings J, Loor G, Green JS. Respiratory Failure due to Possible Donor-Derived *Sporothrix schenckii* Infection in a Lung Transplant Recipient. *Case Reports in Infectious Diseases*. 2015;2015(1):925718. doi:10.1155/2015/925718.
- da Silva LM, de Mattos Oliveira F, Hochhegger B, Severo LC. Pulmonary sporotrichosis in Brazil: A case report and review. *Rev. patol. trop*. 2013; 42:121-5. doi:10.5216/rpt.v42i1.23599.
- Orofino-Costa R, Unterstell N, Gripp AC, de Macedo PM, Brota A, Dias E, et al. Pulmonary cavitation and skin lesions mimicking tuberculosis in a HIV



- negative patient caused by *Sporothrix brasiliensis*. Medical mycology case reports. 2013;2:65-71. [doi:10.1016/j.mmmr.2013.02.004](https://doi.org/10.1016/j.mmmr.2013.02.004).
13. Tiwari A, Malani AN. Primary pulmonary sporotrichosis: Case report and review of the literature. Infectious Diseases in Clinical Practice. 2012;20(1):25-7. [doi:10.1097/IPC.0b013e318234c36a](https://doi.org/10.1097/IPC.0b013e318234c36a).
  14. Callens SF, Kitelete F, Lukun P, Lelo P, Van Rie A, Behets F, et al. Pulmonary *Sporothrix schenckii* infection in a HIV positive child. Journal of tropical pediatrics. 2005;52(2):144-6. [doi:10.1093/tropej/fmi101](https://doi.org/10.1093/tropej/fmi101).
  15. Mehta A, Budev MM, Ranes J, Shrestha R. Primary pulmonary sporotrichosis: a case report. Chest. 2004;126(4):945S. [doi:10.1378/chest.126.2.518](https://doi.org/10.1378/chest.126.2.518).
  16. Zhou CH, Asuncion A, Love GL. Laryngeal and respiratory tract sporotrichosis and steroid inhaler use. Archives of pathology & laboratory medicine. 2003;127(7):893-4. [doi:10.5858/2003-127-893-LARTSA](https://doi.org/10.5858/2003-127-893-LARTSA).
  17. Byrd RP, Hourany J, Cooper C, Roy TM. False-positive antineutrophil cytoplasmic antibodies in a patient with cavitary pulmonary sporotrichosis. The American journal of medicine. 1998;104(1):101-3. [doi:10.1016/S0002-9343\(97\)00348-3](https://doi.org/10.1016/S0002-9343(97)00348-3).
  18. Gori S, Lupetti A, Moscato G, Parenti M, Lofaro A. Pulmonary sporotrichosis with hyphae in a human immunodeficiency virus-infected patient. Acta cytologica. 1997;41(2):519-21. [doi:10.1159/000332549](https://doi.org/10.1159/000332549).
  19. Tambini R, Farina C, Fiocchi R, Dupont B, Guého B, Delvecchio G, et al. Possible pathogenic role for *Sporothrix cyanescens* isolated from a lung lesion in a heart transplant patient. Journal of medical and veterinary mycology. 1996;34(3):195-8. [doi:10.1080/09688179608840000](https://doi.org/10.1080/09688179608840000).
  20. Breeling JL, Weinstein L. Pulmonary sporotrichosis treated with itraconazole. Chest. 1993;103(1):313-4. [doi:10.1378/chest.103.1.313](https://doi.org/10.1378/chest.103.1.313).
  21. Padhye AA, Kaufman L, Durry E, Banerjee CK, Jindal SK, Talwar P, et al. Fatal pulmonary sporotrichosis caused by *Sporothrix schenckii* var. *luriei* in India. Journal of Clinical Microbiology. 1992;30(9):2492-4. [doi:10.1128/jcm.30.9.2492-2494.1992](https://doi.org/10.1128/jcm.30.9.2492-2494.1992).
  22. Haponik EF, Hill MK, Craighead CC. Case report: pulmonary sporotrichosis with massive hemoptysis. The American journal of the medical sciences. 1989;297(4):251-3. [doi:10.1097/0000441-198904000-00011](https://doi.org/10.1097/0000441-198904000-00011).
  23. Fields CL, Ossorio MA, Roy TM. Empyema associated with pulmonary sporotrichosis. Southern Medical Journal. 1989;82(7):910-3. [doi:10.1097/00007611-198907000-00029](https://doi.org/10.1097/00007611-198907000-00029).
  24. Velji AM, Hoeprich PD, Slovak R. Multifocal Systemic Sporotrichosis with Lobar Pulmonary Involvement. Scandinavian journal of infectious diseases. 1988;20(5):565-9. [doi:10.3109/00365548809032508](https://doi.org/10.3109/00365548809032508).
  25. Dall L, Salzman G. Treatment of pulmonary sporotrichosis with ketoconazole. Reviews of infectious diseases. 1987;9(4):795-8. [doi:10.1093/clinids/9.4.795](https://doi.org/10.1093/clinids/9.4.795).
  26. PLUSS JL, OPAL SM. Pulmonary sporotrichosis: review of treatment and outcome. Medicine. 1986;65(3):143-53. [doi:N/A](https://doi.org/10.1093/med/65.3.143).
  27. PUERINGER RJ, IBER C, DEIKE MA, DAVIES SF. Spontaneous remission of extensive pulmonary sporotrichosis. Annals of internal medicine. 1986;104(3):366-7. [doi:N/A](https://doi.org/10.7326/0000441-19861043-00007).
  28. University of Stellenbosch and Tygerberg Hospital, Parowvallei CP. Systemic sporotrichosis-pulmonary complications of a well-known cutaneous fungal disease-a case report. South African Medical Journal. 1982;62(13):451-3. [doi:N/A](https://doi.org/10.1185/00071226826213451).
  29. Rohatgi PK. Pulmonary sporotrichosis. Southern Medical Journal. 1980;73(12):1611-7. [doi:10.1097/00007611-198012000-00023](https://doi.org/10.1097/00007611-198012000-00023).
  30. Jung JY, Almond CH, Campbell DC, Elkadi A, Tenorio A. Role of surgery in the management of pulmonary sporotrichosis. The Journal of Thoracic and Cardiovascular Surgery. 1979;77(2):234-9. [doi:10.1016/S0022-5223\(19\)40962-8](https://doi.org/10.1016/S0022-5223(19)40962-8).
  31. Lowenstein M, Markowitz SM, Nottebart HC, Shadomy S. Existence of *Sporothrix schenckii* as a pulmonary saprophyte. Chest. 1978;73(3):419-21. [doi:10.1378/chest.73.3.419](https://doi.org/10.1378/chest.73.3.419).
  32. Zvetina JR, Rippon JW, Daum V. Chronic pulmonary sporotrichosis. Mycopathologia. 1978;64:53-7. [doi:10.1007/BF00443090](https://doi.org/10.1007/BF00443090).
  33. Berson SD, Brandt FA. Primary pulmonary sporotrichosis with unusual fungal morphology. Thorax. 1977;32(4):505-8. [doi:10.1136/thx.32.4.505](https://doi.org/10.1136/thx.32.4.505).
  34. Michelson E. Primary pulmonary sporotrichosis. The Annals of Thoracic Surgery. 1977;24(1):83-6. [doi:10.1016/S0003-4975\(10\)64578-X](https://doi.org/10.1016/S0003-4975(10)64578-X).
  35. Kinas HY, Smulewicz JJ. Primary pulmonary sporotrichosis. Respiration. 1976;33(6):468-74. [doi:10.1159/000193764](https://doi.org/10.1159/000193764).
  36. Serstock DS, Zinneman HH. Pulmonary and articular sporotrichosis: report of two cases. JAMA. 1975;233(12):1291-3. [doi:10.1001/jama.1975.03260120053021](https://doi.org/10.1001/jama.1975.03260120053021).
  37. Evers RH, Whereatt RR. Pulmonary sporotrichosis. Chest. 1974;66(1):91-2. [doi:10.1378/chest.66.1.91](https://doi.org/10.1378/chest.66.1.91).
  38. Mohr JA, Patterson CD, Eaton BG, Rhoades ER, Nichols NB. Primary pulmonary sporotrichosis. American Review of Respiratory Disease. 1972;106(2):260-4. [doi:10.1164/arrd.1972.106.2.260](https://doi.org/10.1164/arrd.1972.106.2.260).
  39. Smith AG, Morgan WK, Hornick RB, Funk AM. Chronic pulmonary sporotrichosis: Report of a case, including morphologic and mycologic studies. American Journal of Clinical Pathology. 1970;54(3):401-9. [doi:10.1093/ajcp/54.3.401](https://doi.org/10.1093/ajcp/54.3.401).
  40. Baum GL, Donnerberg RL, Stewart D, Mulligan WJ, Putnam LR. Pulmonary sporotrichosis. New England Journal of Medicine. 1969;280(8):410-3. [doi:10.1056/NEJM196902202800803](https://doi.org/10.1056/NEJM196902202800803).
  41. Kobayashi G, Newmark LN, Wessler S, Avioli LV. Pulmonary sporotrichosis. JAMA. 1969;210(9):1741-4. [doi:10.1001/jama.1969.03160350053010](https://doi.org/10.1001/jama.1969.03160350053010).
  42. McGavran MH, Kobayashi G, Newmark L, Newberry M, Miller CA, Harford CG. Pulmonary sporotrichosis. Diseases of the Chest. 1969;56(6):547-9. [doi:10.1378/chest.56.6.547](https://doi.org/10.1378/chest.56.6.547).
  43. Beland JE, Mankiewicz E, MacIntosh DJ. Primary pulmonary sporotrichosis. Canadian Medical Association Journal. 1968;99(16):813. [doi:N/A](https://doi.org/10.1503/cmaj).
  44. Trevathan RD, Phillips S. Primary pulmonary sporotrichosis: Case report. JAMA. 1966;195(11):965-7. [doi:10.1001/jama.1966.03100110133046](https://doi.org/10.1001/jama.1966.03100110133046).
  45. Siegrist, Helen D., Ferrington, Elizabeth. (1965). Primary Pulmonary Sporotrichosis. Southern Medical Journal, 58(6), 728-735. [doi:10.1097/00007611-196506000-00010](https://doi.org/10.1097/00007611-196506000-00010).
  46. Ridgeway NA, Whitcomb FC, Erickson EE, Law SW. Primary pulmonary sporotrichosis: Report of two cases. The American Journal of Medicine. 1962;32(1):153-60. [doi:10.1016/0002-9343\(62\)90193-6](https://doi.org/10.1016/0002-9343(62)90193-6).
  47. Scott SM, Peasley ED, Crymes TP. Pulmonary sporotrichosis: Report of two cases with cavitation. New England Journal of Medicine. 1961;265(10):453-7. [doi:10.1056/NEJM196109072651001](https://doi.org/10.1056/NEJM196109072651001).
  48. POST GW, JACKSON A, Garber PE, Veach GE. Pulmonary sporotrichosis. Diseases of the Chest. 1958;34(4):455-9. [doi:10.1378/chest.34.4.455](https://doi.org/10.1378/chest.34.4.455).
  49. Aung AK, Spelman DW, Thompson PJ. Pulmonary sporotrichosis: an evolving clinical paradigm. In Seminars in respiratory and critical care medicine. 2015;36(5):756-766. [doi:10.1055/s-0035-1562901](https://doi.org/10.1055/s-0035-1562901).
  50. Quintal D. Sporotrichosis infection on mines of the Witwatersrand. Journal of cutaneous medicine and surgery. 2000;4(1):51-4. [doi:10.1177/120347540000400113](https://doi.org/10.1177/120347540000400113).
  51. Falcão EM, de Lima Filho JB, Campos DP, Valle AC, Bastos FI, Gutierrez-Galhardo MC, et al. Hospitalizaciones y óbitos relacionados con la esporotricosis en Brasil (1992-2015). Cadernos de Saude Publica. 2019;35:e00109218. [doi:10.1590/0102-311X00109218](https://doi.org/10.1590/0102-311X00109218).
  52. Benedict K, Jackson BR. Sporotrichosis cases in commercial insurance data, United States, 2012-2018. Emerging Infectious Diseases. 2020;26(11):2783. [doi:10.3201%2Feid2611.201693](https://doi.org/10.3201%2Feid2611.201693).
  53. COMSTOCK C, WOLSON AH. Roentgenology of sporotrichosis. American Journal of Roentgenology. 1975;125(3):651-5. [doi:10.2214/ajr.125.3.651](https://doi.org/10.2214/ajr.125.3.651).