


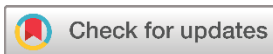Systematic Review

Breast Carcinoma within Fibroadenoma: A Systematic Review

Abdulwahid M. Salih^{1*} , Lana R.A. Pshtiwan¹, Mohammed Gh. Hamasaeed¹, Sami S. Omar², Shaban Latif¹, Shadi H. Sidiq³, Bushra O. Hussein¹, Hunar A. Hassan⁴, Diyar A. Omar⁵, Sarhang S. Abdalla¹, Hemn A. Hassan⁴, Yousif M. Mahmood¹, Marwan N. Hassan¹, Dahat A. Hussein⁶, Sasan M. Ahmed⁷, Hiwa O. Abdullah⁶, Berun A. Abdalla⁸

1. Scientific Affairs Department, Smart Health Tower, Madam Mitterrand Street, Sulaymaniyah, Iraq
2. Rizgary Oncology Center, Peshawa Qazi Street, Erbil, Iraq
3. Department of Nursing, Raparin Technical and Vocational Institute, Rania, Iraq
4. Kscien Organization for Scientific Rsearch (Middle East Office), Hamid Street, Azadi Mall, Sulaymaniyah, Iraq
5. Medical Laboratory Technology, Shaqlawa Technical College, Erbil Polytechnic University, Erbil, Iraq
6. Department of Biology, College of Science, University of Sulaimani, Sulaymaniyah, Iraq
7. Department of Family and Community Medicine, College of Medicine, University of Sulaimani, Sulaymaniyah, Iraq
8. Department of Biology, College of Education, University of Sulaimani, Madam Mitterrand Street, Sulaymaniyah, Iraq

* **Corresponding author:** A.salih@smartglobalholding.co.uk (A.M. Salih). Ablagh, House number 80, Zip code: 46001, Sulaymaniyah, Iraq

**Keywords:**

Fibroadenoma
Breast cancer
Ductal carcinoma in situ
Lobular carcinoma in situ
Invasive ductal carcinoma

Received: October 20, 2024

Revised: November 18, 2024

Accepted: November 25, 2024

Published: November 30, 2024

Copyright: © 2024 Salih et al. This is an open access article distributed under the terms of the Creative Commons Attribution License (<https://creativecommons.org/licenses/by/4.0/>), which permits unrestricted use, distribution, and reproduction in any medium, provided the original author and source are credited.

Citation: Salih AM, Pshtiwan LR, Hamasaeed MGh, Omar SS, Latif Sh, Sidiq SH et al. Breast Carcinoma within Fibroadenoma: A Systematic Review. Barw Medical Journal. 2024 Nov 30;2(4): 32-49.
<https://doi.org/10.58742/bmj.v2i4.144>

Abstract

Introduction

Fibroadenoma is the most common benign breast lesion; however, it carries a potential risk of malignant transformation. This systematic review provides an overview of the presentation, management, and outcome of carcinomas arising within fibroadenomas.

Methods

A systematic search on Google Scholar was conducted for English-language studies on breast carcinoma within fibroadenomas. Studies on fibroadenomas with no malignant components, review articles, pre-prints, incomplete data, and those published in suspicious journals were excluded.

Results

On ultrasonography, 28 masses (36.8%) appeared benign, and 20 (26.3%) were suspicious, with ultrasonographic data unavailable for the remaining tumors (36.8%). Mammography data were available for 50 tumors, revealing 27 benign lesions (54%) and 23 suspicious lesions (46%). Among the 17 lesions with available magnetic resonance imaging data, five were benign lesions (29.4%), and 12 were suspicious (70.6%). Cytology evaluation among 46 tumors revealed that 20 (43.5%) were benign, 24 (52.2%) were malignant, and two (4.3%) were suspicious. The most commonly performed surgery was wide local excision (50.7%), followed by mastectomy (32.9%). On histopathology, 11 tumors exhibited more than one pathology. Ductal carcinoma in situ was the most frequent finding (40.8%), followed by invasive ductal carcinoma (28.9%) and lobular carcinoma in situ (28.4%). Recurrence was observed in one case (1.4%), and metastasis occurred in two cases (2.8%).

Conclusion

Although rare, carcinomas arising within fibroadenomas may present considerable challenges in preoperative diagnosis, whether through imaging or cytology. Therefore, clinicians may find it necessary to approach fibroadenomas with increased caution.

1. Introduction

Fibroadenoma is the most common benign breast lesion comprising epithelial and stromal components [1,2]. The tumor generally manifests as a hyperplastic breast lobule, presenting as a solitary mass during a woman's early reproductive years, with the peak incidence occurring in the second and third decades of life [3,4]. Estrogen, progesterone, pregnancy, and lactation are believed to stimulate tumor growth, although it tends to shrink during menopause as estrogen levels decline [3]. Incidence rates range from 7% to 13% in the general population, with up to 20% of cases presenting with bilateral or multiple masses [3]. Clinically, fibroadenoma presents as a palpable, mobile, solid mass with a rubbery consistency and smooth, well-defined borders [5]. It is radiologically and histologically classified into simple and complex types [2]. The tumor may exceed 3 mm in size, be associated with sclerosing adenosis or epithelial calcifications, and potentially give rise to carcinomas that can invade the surrounding breast tissue. Although cases of fibroadenomas containing malignancies are rare, malignancy tends to occur more frequently in patients 10 to 20 years older than the typical age for simple fibroadenomas [2,6]. Carcinomas within fibroadenomas are most commonly carcinoma in situ (CIS) [7,8]. Invasive carcinomas, though less common, can occur, with invasive ductal carcinoma (IDC) and invasive lobular carcinoma (ILC) being the primary forms [6]. Carcinomas in situ signal an increased risk of developing invasive cancer if left untreated, and neoplasms arising within fibroadenomas behave similarly to those occurring independently [9]. This systematic review provides an overview of the presentation, management, and outcome of carcinomas arising within fibroadenomas.

2. Methods

2.1. Study design

This systematic review followed the Preferred Reporting Items for Systematic Reviews and Meta-Analyses (PRISMA) guidelines.

2.2. Data sources and search strategy

A systematic search on Google Scholar was undertaken to identify relevant English-language studies on breast carcinoma within fibroadenoma. The search strategy employed a combination of keywords, including "fibroadenoma" with terms such as (carcinoma, cancer, malignancy, malignant, carcinoma in situ, lobular carcinoma in situ (LCIS), and ductal carcinoma in situ (DCIS).

2.3. Eligibility criteria

The inclusion criteria were limited to studies specifically addressing breast carcinoma within fibroadenoma. Studies on fibroadenomas with no malignant components, review articles, pre-prints, incomplete data, and those published in suspicious journals were excluded [10].

2.4. Study selection and data extraction

Two authors independently reviewed the titles and abstracts of the identified publications. Following this, the same two authors assessed the full texts of the remaining studies based on predefined inclusion and exclusion criteria. The extracted data included the first author's name, the country of publication, study design, patient demographics, clinical presentation, physical examination findings, imaging and cytology findings, treatment strategies, and disease prognosis.

2.5. Data analysis

Microsoft Excel (2019) was employed to collect and organize the extracted data, while data analysis (descriptive statistics) was performed using the Statistical Package for Social Sciences (SPSS), version 27.0. The results are presented as frequencies, percentages, ranges, mean with standard deviation, and medians with quartile ranges.

3. Results

3.1. Study selection and characteristics

A total of 317 studies were identified from the search. Thirty-six studies were excluded due to duplication (n=5) and non-English language publications (n=31). This left 281 studies for title and abstract screening. At this stage, 202 studies were excluded due to irrelevancy. As a result, 79 studies advanced to the full-text screening stage. At this point, nine studies were excluded for being meta-analyses (n=2), reviews (n=2), publications with incomplete data (n=1), and pre-prints (n=4). Nine of the remaining 70 studies were excluded for failing to meet eligibility criteria as they were published in suspicious journals [10]. Ultimately, 61 studies [1-9,11-62], encompassing 72 cases, were included (Figure 1). Most of the studies were case reports (n=58), accompanied by three case series. Most were affiliated with Japan (19.7%) and the USA (14.7%) (Table 1). The raw data of the study has been presented in Tables 1-6.

3.2. Patients and tumor characteristics

The total number of patients was 72 females, with a mean age of 44.4 ± 13.6 years. Most patients presented with either a breast lump (43.1%) or a mass (30.5%), with a median presentation duration of 12 months. In 80.6% of cases, the disease was unilateral, with laterality distributed almost equally between the right side (42.1%) and the left (39.5%). The mean tumor size was 24.7 ± 13.3 millimeters. The past medical history was negative in 27.8% of cases, while seven cases (9.7%) had a positive history of other breast diseases, including breast mass in four cases and DCIS, fibrocystic breast disease, and IDC per case. The family history of breast cancer was positive in four cases (5.5%). On physical examination, information about the tumor surface was available for nine tumors (11.8%), all of which had a smooth surface. Of the 22 tumors with available data on consistency, 14 (63.6%) were firm, five (22.7%) were hard, and three (13.6%) were rubbery. Among the 28 tumors with existing mobility data, 25 (89.3%) were found to be mobile. Axillary lymphadenopathy was reported in four tumors (5.3%). On ultrasonography, 28 masses appeared benign (36.8%), and 20 cases were suspicious (26.3%), with ultrasonographic data unavailable for the remaining tumors (36.8%). Mammography

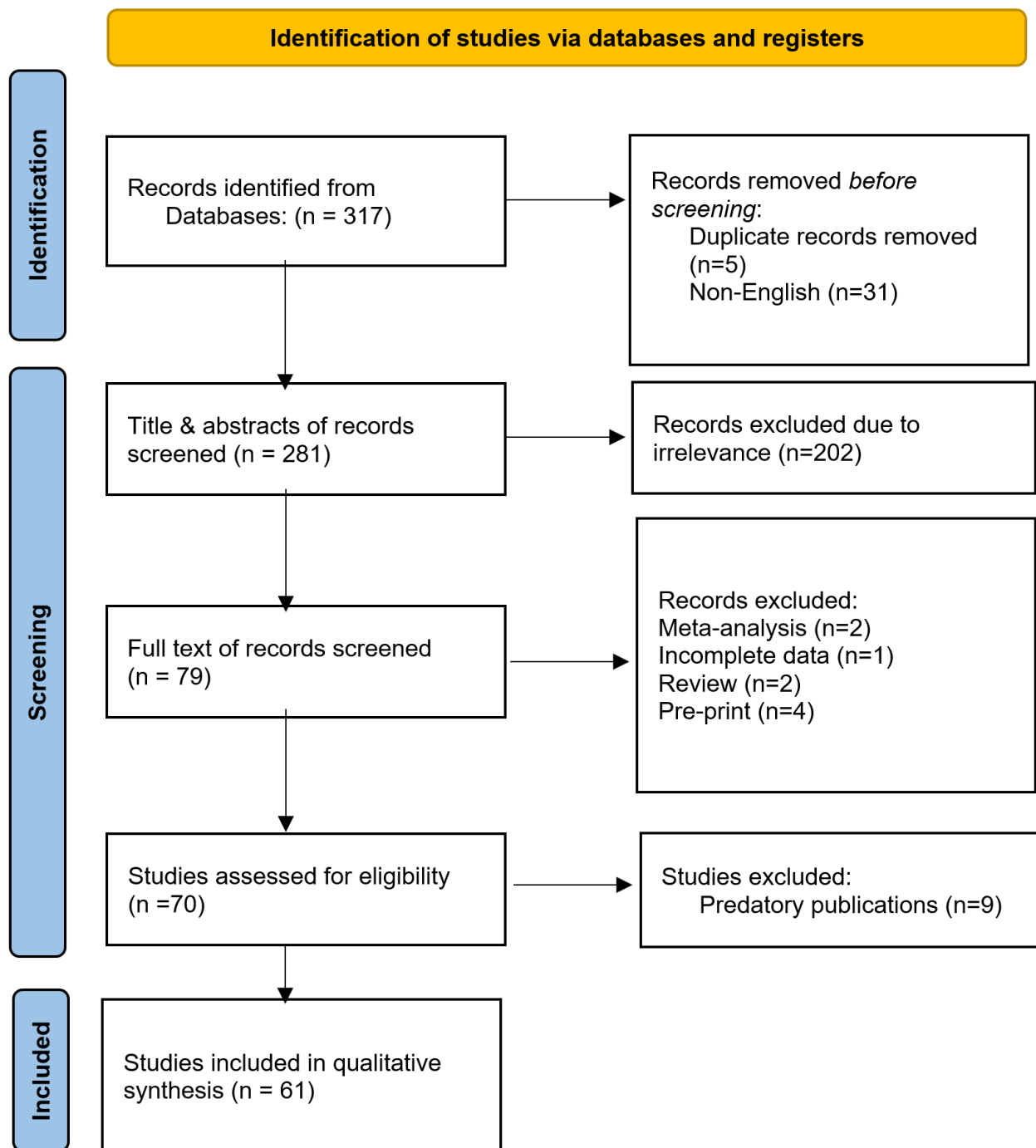


Figure 1. Study selection PRISMA flow chart.

data were available for 50 tumors, revealing 27 benign lesions (54%) and 23 suspicious lesions (46%). Among the 17 lesions with available magnetic resonance imaging (MRI) data, five were benign lesions (29.4%), and 12 were suspicious (70.6%). Core needle biopsy (CNB) or fine needle aspiration cytology (FNAC) revealed that 20 tumors (26.3%) were benign, 24 (31.6%) were malignant, and two (2.6%) were suspicious. The data on preoperative diagnosis was unavailable for 30 cases (39.5%). (Table 7)

3.3. Management and outcome

The most commonly performed surgery was wide local excision (50.7%), followed by mastectomy (32.9%). Axillary lymph node dissection was carried out in 43.9% of cases. A total of 11 cases (15.3%) received chemotherapy, 16 cases (22.2%) underwent radiotherapy, and hormonal therapy was prescribed for 20 cases (27.8%). On histopathological examination, 11 tumors exhibited more than one pathology. DCIS was the most frequent finding (40.8%), followed by IDC (28.9%) and LCIS

Table 1. The distribution of the reported cases among countries.

Author /Year [reference]	Study design	No. of included case(s)	Country
Ni et al./2023 [14]	Case report	1	China
Brunetti et al./2023 [4]	Case report	1	Italy
Wang et al./2022 [5]	Case report	1	Singapore
Pang et al./2022 [2]	Case report	1	Malaysia
Hammood et al./2022 [3]	Case report	1	Iraq
Tagliati et al./2021 [1]	Case report	1	Italy
Shojaku et al./2021 [6]	Case report	1	Japan
Fujimoto et al./2021 [11]	Case report	1	Japan
Feijó et al./2021[8]	Case report	1	Brazil
Shiino et al./2020 [12]	Case report	1	Japan
Moreno et al./2020 [17]	Case report	1	Brazil
Gonthong et al./2020 [13]	Case report	1	Thailand
El-Essawy et al./2020 [18]	Case report	1	KSA
Brock et al./2020 [9]	Case report	1	USA
Marumoto et al./2019 [16]	Case report	1	USA
Zeeshan et al./2018 [19]	Case report	1	Pakistan
Tiwari et al./2018 [15]	Case report	1	India
Frisch et al./2018 [7]	Case report	1	South Africa
Lim et al./2017 [20]	Case report	1	Korea
You et al./2016 [21]	Case report	1	Korea
Zheng et al./2015 [22]	Case report	1	China
Hua et al./2015 [23]	Case report	1	China
Wu et al./2014 [24]	Case series	6	Taiwan
Mele et al./2014 [25]	Case report	1	Denmark
Limite et al./2014 [26]	Case report	1	Italy
Kwon et al./2014 [27]	Case report	1	Korea
Kılıç et al./2014 [28]	Case report	1	Turkey
Dandin et al./2014 [29]	Case report	1	Turkey
Buteau et al./2014 [30]	Case report	1	USA
Hayes et al./2013 [31]	Case report	1	Ireland
Jahan et al./2012 [32]	Case report	1	Bangladesh
Butler et al./2012 [33]	Case report	1	USA
Ooe et al./2011 [34]	Case report	1	Japan
Lin et al./2011 [35]	Case report	1	Taiwan
Kato et al./2011 [36]	Case report	1	Japan
Abu-Rahmeh et al./ 2012 [37]	Case report	1	Israel
Rao et al./ 2010 [38]	Case report	1	India
Petersson et al./2010 [39]	Case report	1	Singapore
Tajima et al./2009 [40]	Case report	1	Japan
Gashi-Luci et al./2009 [41]	Case report	1	Kosova
Borecky et al./2008 [42]	Case series	3	Australia
Tiu et al./2006 [43]	Case report	1	Taiwan
Shin et al./2006 [44]	Case report	1	Korea
Blanco et al./2005 [45]	Case report	1	USA
Abite et al./2005 [46]	Case report	1	Nigeria
Stafyla et al./2004 [47]	Case report	1	Greece
Abe et al./ 2004 [48]	Case report	1	Japan
Adelekan et al./2003 [49]	Case report	1	UK

Table 1. Continued....

Yano et al./2001 [50]	Case report	1	Japan
Gebrim et al./2000 [51]	Case report	1	Brazil
Psarianos et al./1998 [52]	Case report	1	Australia
Shah et al./ 1998 [53]	Case report	1	USA
Kurosum et al./1994 [54]	Case report	1	Japan
Morimoto et al./1993 [55]	Case report	1	Japan
Gupta et al./1992 [56]	Case report	1	New Zealand
Gupta et al./1991 [57]	Case report	1	New Zealand
Fukud et al./1989 [58]	Case report	1	Japan
Yoshida et al./1985 [59]	Case report	1	Japan
Fond et al./1979 [60]	Case report	1	USA
Konakry et a./1975 [61]	Case series	5	USA
Durso et al./1972 [62]	Case report	1	USA

(28.4%). Immunohistochemical analysis showed that 20 out of 40 tumors (50%) were positive for both estrogen (ER) and progesterone receptors (PR). Of the 39 tumors with reported axillary status, 82.1% had negative axillary findings. The median follow-up period was 24 months, with quartile ranges of 10 to 36 months. Recurrence was observed in one case (1.4%), and metastasis occurred in two cases (2.8%) (Table 7)

4. Discussion

Carcinomas and high-risk lesions within fibroadenomas can either originate from the fibroadenoma itself and remain entirely encapsulated, or they can involve both the fibroadenoma and the adjacent breast tissue [2]. While rare, a small percentage of fibroadenomas may contain carcinomas or high-risk lesions, with reported incidence rates ranging from 0.002% to 0.125%. Fibroadenomas with malignant components are primarily found in patients 10 to 20 years older than the typical age for simple fibroadenomas [2]. In this systematic review, the mean age of affected patients was 44.4 years, further highlighting the trend of malignancies occurring in later decades of life.

The role of fibroadenomas as a potential risk factor for breast cancer is still not fully established [8]. It has been suggested that they may represent a long-term risk factor for breast cancer, particularly in women with complex fibroadenomas, proliferative disease, or a family history of breast cancer. Specifically, complex fibroadenomas are associated with a relative breast cancer risk that is approximately 3.10 times greater [6]. Another significant indicator of potential malignant transformation in fibroadenomas is the progressive mass size and thickness increase with advancing patient age [3]. A study has reported that the average tumor diameter of breast cancer occurring within a fibroadenoma is 2.46 cm [11]. Similarly, the mean tumor size in this systematic review was 2.47 ± 13.3 cm.

Frisch et al. reported that the predominant form of malignancy associated with breast cancer arising in fibroadenomas was CIS, with LCIS accounting for 66.9% and DCIS comprising 12.4%. Additionally, IDCs were more frequent among the invasive cases than ILCs [7]. Conversely, another study found that ductal and lobular carcinomas occur with equal frequency [6]. In this study, the distribution of malignancies within fibroadenomas

Table 2. Patient demography, disease presentation, and medical history

First Author /Year	Age (years)	Gender	Presentation	Laterality	Duration (months)	PMH	FHx of breast cancer
Ni et al./2023 [14]	60	F	Mass	UL	12	NN	Neg.
Brunetti et al./2023 [4]	35	F	Lump	UL	NA	NN	FDR
Wang et al./2022 [5]	26	F	Lump	UL	72	NN	NA
Pang et al./2022 [2]	43	F	Nipple discharge	UL	NA	BM	Neg.
Hammood et al./2022 [3]	49	F	Lump	UL	60	BM	Neg.
Tagliati et al./2021 [1]	49	F	Lump	UL	NA	NA	Neg.
Shojaku et al./2021 [6]	61	F	Mass	UL	60	NN	Neg.
Fujimoto et al./2021 [11]	31	F	Mass	UL	12	NN	Neg.
Feijó et al./2021[8]	31	F	Lump	UL	48	NA	Neg.
Shiino et al./2020 [12]	53	F	Lump	UL	156	NA	NA
Moreno et al./2020 [17]	58	F	Lump	UL	NA	NA	NA
Gonthong et al./2020 [13]	38	F	Mass	UL	NA	IDC	NA
El-Essawy et al./2020 [18]	25	F	Mass	UL	1	MBBM	Neg.
Brock et al./2020 [9]	27	F	Lump	UL	4	FBD	NA
Marumoto et al./2019 [16]	70	F	Mass	UL	NA	NA	Neg.
Zeeshan et al./2018 [19]	34	F	Lump	UL	12	NN	NA
Tiwari et al./2018 [15]	28	F	Lump	BL	96	NN	Neg.
Frisch et al./2018 [7]	18	F	Lump	UL	48	NN	Neg.
Lim et al./2017 [20]	20	F	Nodule	UL	NA	NN	Neg.
You et al./2016 [21]	38	F	Incidental	UL	NA	NA	Neg.
Zheng et al./2015 [22]	48	F	Lump	BL	NA	NA	NA
Hua et al./2015 [23]	44	F	Lump	BL	12	NA	NA
	39	F	NA	NA	24	NA	NA
	31	F	NA	NA	84	NA	NA
Wu et al./2014 [24]	30	F	NA	NA	NA	NA	NA
	63	F	NA	NA	0.5	NA	NA
	48	F	NA	NA	3	NA	NA
	40	F	NA	NA	0	NA	NA
Mele et al./2014 [25]	63	F	NA	UL	NA	NA	Pos.
Limite et al./2014 [26]	26	F	Lump	UL	NA	NA	Neg.
Kwon et al./2014 [27]	20	F	Lump	BL	1	NN	Neg.
Kılıç et al./2014 [28]	30	F	Mass	UL	NA	NA	Neg.
Dandin et al./2014 [29]	35	F	Mass	UL	1.5	NN	Neg.
Buteau et al./2014 [30]	59	F	Mass	UL	36	NN	Neg.
Hayes et al./2013 [31]	51	F	Incidental	NA	NA	NA	NA
Jahan et al./2012 [32]	55	F	Lump	BL	240	NA	NA
Butler et al./2012 [33]	46	F	Mass	NA	60	NA	NA
Ooe et al./2011 [34]	46	F	Lump	UL	60	NN	Neg.
Lin et al./2011 [35]	34	F	Lump	UL	NA	NN	Neg.
Kato et al./2011 [36]	42	F	Mass	UL	NA	NA	NA
Abu-Rahmeh et al./ 2012 [37]	69	F	Mass	UL	168	NA	FDR
Rao et al./ 2010 [38]	30	F	Lump	UL	1	NN	Neg.
Petersson et al./2010 [39]	49	F	Incidental	UL	48	NA	NA
Tajima et al./2009 [40]	60	F	Mass	UL	3	NA	NA
Gashi-Luci et al./2009 [41]	39	F	Lump	UL	2	NA	Neg.
	64	F	Mass	UL	NA	NA	NA
Borecky et al./2008 [42]	80	F	Lump	UL	600	NA	NA
	53	F	NA	UL	NA	NA	NA

Table 2. Continued....

Tiu et al./2006 [43]	45	F	Lump	UL	60	NN	NA
Shin et al./2006 [44]	51	F	Mass	UL	12	NN	Neg.
Blanco et al./2005 [45]	63	F	Mass	UL	60	NN	Neg.
Abite et al./2005 [46]	23	F	Lump	UL	12	NA	Neg.
Stafyla et al./2004 [47]	27	F	Mass	UL	NA	NA	NA
Abe et al./ 2004 [48]	42	F	Lump	UL	3	NN	Neg.
Adelekan et al./2003 [49]	61	F	Lump	BL	120, 0.75	NA	NA
Yano et al./2001 [50]	54	F	Mass	UL	36	NA	Neg.
Gebrim et al./2000 [51]	58	F	Nodule	UL	NA	NA	NA
Psarianos et al./1998 [52]	34	F	Mass	UL	NA	NA	NA
Shah et al./ 1998 [53]	45	F	Mass	UL	0.25	NA	Neg.
Kurosum et al./1994 [54]	42	F	Lump	UL	21	NA	NA
Morimoto et al./1993 [55]	49	F	Lump	UL	2	NA	NA
Gupta et al./1992 [56]	59	F	Mass	UL	0.5	NN	Neg.
Gupta et al./1991 [57]	49	F	Mass	UL	7	NA	Neg.
Fukud et al./1989 [58]	45	F	Lump	UL	NA	BM	NA
Yoshida et al./1985 [59]	58	F	Lump	UL	1	HTN	Neg.
Fond et al./1979 [60]	27	F	Lump	UL	NA	CAH	SDR
	59	F	NA	UL	NA	NA	NA
	39	F	NA	UL	NA	NA	NA
Konakry et a./1975 [61]	44	F	NA	UL	NA	NA	NA
	46	F	NA	UL	NA	DCIS	NA
	48	F	NA	UL	NA	NA	NA
Durso et al./1972 [62]	42	F	Lump	UL	NA	NA	NA

F: female, PMH: Past Medical History, FHx: Family History, UL: Unilateral, BL: bilateral, NA: Non-available, BM: Breast Mass, NN: Nothing Noteworthy, IDC: Invasive Ductal Carcinoma, MBBM: Multiple Bilateral Breast Mass, FBD: Fibrocystic Breast Disease, HTN: Hypertension, CAH: Congenital Adrenal Hyperplasia, DCIS: Ductal Carcinoma In Situ, FDR: First-Degree Relative, SDR: Second-Degree Relative, Neg.: Negative, Pos.: Positive.

revealed distinct differences from Frisch et al.'s study [7]. for 40.8% of tumors and LCIS represented 28.4% of tumors. The incidence of IDC was higher in this review at 28.9%, compared to 11% in the prior study [7]. Additionally, rarer malignancies like acinic cell carcinoma, adenoid cystic carcinoma, and invasive apocrine carcinoma were observed, suggesting a broader spectrum of tumor types associated with fibroadenomas than traditionally recognized.

The neoplastic proliferation of epithelial cells within the breast lobule characterizes LCIS. It is considered a precursor to ILC, similar to the relationship between DCIS and IDC. LCIS is now recognized as a general marker for breast cancer risk rather than a definitive pre-cancerous condition. It has been indicated that neoplasms within fibroadenomas behave similarly and have comparable prognoses to those occurring independently [9]. DCIS, also known as intraductal carcinoma, is a neoplasm that does not invade the basement membrane. This type of breast carcinoma develops within the ductal system, particularly in the terminal lobular duct unit. Although DCIS cannot metastasize and is considered non-lethal, its presence indicates an increased risk of developing invasive cancer if left untreated [8].

The preoperative diagnosis of malignant transformation within fibroadenoma is difficult and often necessitates surgical

intervention for definitive confirmation [3]. This challenge stems from the overlap in clinical and radiological features between benign and malignant fibroadenomas, making it difficult to distinguish between the two preoperatively [4]. However, certain imaging characteristics can help identify carcinoma within fibroadenomas. Such malignancies tend to present with larger size, irregular shape, poorly defined margins, and abnormal calcifications, including linear, pleomorphic, or microcalcifications [12]. Sonographic evaluation of carcinomas within fibroadenomas typically reveals irregular lesions with indistinct borders. These tumors are often associated with marked hypoechoic shadowing, an echogenic halo, and distortion of surrounding tissue. Ultrasound is beneficial for tumor size assessment due to its high-resolution imaging capabilities. While mammography may reveal indistinct borders and microcalcifications, it is insufficient for diagnosing fibroadenomas with underlying carcinoma. Nonetheless, microcalcifications on mammography remain a valuable indicator of malignant transformation [3]. When calcifications are identified on mammography, ultrasound can be used to evaluate the invasiveness of the lesion and guide biopsy. Additionally, Doppler color imaging provides further insights into the internal vascularity of the tumor [13]. Dynamic MRI offers a reliable method for distinguishing malignant

Table 3. The characteristics of the tumors.

First Author. /Year	Physical examination			Ax LAD	Size	Location	Shape	Margin	Vascularity	Calcification
	Surface	Consistency	Mobility							
Ni et al./2023 [14]	NA	NA	NM	Neg.	7.7 mm	RUA	Round	Smooth	NA	Pos.
Brunetti et al./2023 [4]	NA	NA	M	Neg.	15 mm	LLA	Oval	Well defined	NA	NA
Wang et al./2022 [5]	NA	NA	NA	NA	24 mm	LT	NA	Irregular	NA	NA
Pang et al./2022 [2]	NA	NA	NA	NA	16.7 mm	ROA	Oval	Lobulated	Moderate	Neg.
Hammood et al./2022 [3]	Smooth	Firm	NM	NA	9.5mm	RT	Oval	Well defined	NA	NA
Tagliati et al./2021 [1]	NA	NA	NA	NA	35 mm	RT	Oval	Well defined	NA	NA
Shojaku et al./2021 [6]	NA	Hard	NA	NA	11.9 mm	LT	Oval	Well defined	NA	Neg.
Fujimoto et al./2021 [11]	NA	NA	NA	Neg.	22 mm	LT	NA	Well defined	NA	Pos.
Feijó et al./2021[8]	NA	NA	NA	Neg.	30 mm	LUOQ	NA	Well defined	Neg.	Neg.
Shiino et al./2020 [12]	NA	Hard	NA	Pos.	36 mm	RLIQ	NA	Ill defined	NA	Pos.
Moreno et al./2020 [17]	NA	NA	NA	Pos.	9.8 mm	LUOQ	NA	NA	NA	NA
Gonthong et al./2020 [13]	NA	NA	NA	NA	20 mm	RT	Oval	Microlobulated	NA	Pos.
El-Essawy et al./2020 [18]	NA	NA	NA	NA	28.7 mm	LIA	NA	Irregular	Increased	Pos.
Brock et al./2020 [9]	NA	Firm	M	NA	19.8 mm	LOA	NA	NA	NA	Neg.
Marumoto et al./2019 [16]	NA	NA	M	Neg.	20.4 mm	RUOQ	NA	Irregular	NA	Neg.
Zeeshan et al./2018 [19]	NA	NA	M	NA	47.9 mm	RRA	NA	Lobulated	NA	NA
Tiwari et al./2018 [15]	Smooth	Firm	M	NA	NA	BL	NA	Well defined	NA	NA
Frisch et al./2018 [7]	NA	NA	M	Neg.	39.3 mm	RLIQ	NA	Well defined	Neg.	Neg.
Lim et al./2017 [20]	NA	NA	NA	NA	64.8 mm	RUA	NA	NA	NA	NA
You et al./2016 [21]	NA	NA	NA	Neg.	6.9 mm	RUIQ	Oval	Well defined	NA	Pos.
Zheng et al./2015 [22]	NA, Smooth	NA, NA	NA, M	Neg., Neg.	24.5 mm, NA	LUA, RUIQ	NA, NA	Ill defined, well defined	NA, NA	NA, Pos.
Hua et al./2015 [23]	NA	NA	NA	NA	22.4 mm	LT	NA	Well defined	Moderate	Pos.
	NA	NA	NA	NA	27 mm	NA	NA	NA	NA	NA
	NA	NA	NA	NA	34.5 mm	NA	NA	NA	NA	NA
Wu et al./2014 [24]	NA	NA	NA	NA	14.5 mm	NA	NA	NA	NA	NA
	NA	NA	NA	NA	12 mm	NA	NA	NA	NA	NA
	NA	NA	NA	NA	9 mm	NA	NA	NA	NA	NA
	NA	NA	NA	NA	6 mm	NA	NA	NA	NA	NA
Mele et al./2014 [25]	NA	NA	NA	Pos.	50 mm	LLOQ	NA	Well defined	NA	Pos.
Limite et al./2014 [26]	Smooth	Hard	M	Neg.	1.8 mm	RLA	NA	Ill defined	NA	NA
Kwon et al./2014 [27]	NA, NA	Firm, Firm	M, M	Neg., Neg.	16.9 mm, 21.9 mm	RT, LT	NA, Oval	Lobulated, Irregular	NA, NA	Pos., Pos.
Kılıç et al./2014 [28]	NA	Firm	NA	Neg.	19.9 mm	LRA	NA	Well defined	NA	Pos.
Dandin et al./2014 [29]	NA	NA	M	Neg.	11.8 mm	LUOQ	Oval	Irregular	NA	NA
Buteau et al./2014 [30]	NA	NA	NA	Pos.	17 mm	LT	Lobular	NA	NA	NA
Hayes et al./2013 [31]	NA	NA	NA	NA	35 mm	NA	Multilobulated	Circumscribed	NA	Pos.
Jahan et al./2012 [32]	NA, NA	NA, NA	NA, NA	NA, NA	39.2 mm, 36.3 mm	NA, NA	NA, NA	NA, NA	NA, NA	NA, NA
Butler et al./2012 [33]	NA	NA	NA	NA	7.3 mm	NA	Oval	Well defined	NA	NA
Ooe et al./2011 [34]	Smooth	Firm	M	Neg.	25 mm	RUOQ	Oval	Well defined	Increased	Pos.
Lin et al./2011 [35]	NA	NA	M	Neg.	NA	RUA	Oval	Well defined	NA	Pos.
Kato et al./2011 [36]	NA	Hard	NA	NA	15 mm	RT	Irregular	NA	NA	Pos.

Table 3. Continued....

Abu-Rahmeh et al./ 2012 [37]	NA	NA	NA	NA	50 mm	LT	NA	Well defined	NA	NA
Rao et al./ 2010 [38]	NA	Firm	M	NA	28.3 mm	RUA	Oval	Smooth	NA	Pos.
Petersson et al./2010 [39]	NA	NA	NA	NA	30 mm	NA	NA	Well defined	NA	NA
Tajima et al./2009 [40]	NA	NA	M	NA	16.6 mm	RUIQ	Lobular	Irregular	NA	Pos.
Gashi-Luci et al./2009 [41]	NA	NA	NA	Neg.	20 mm	RUOQ	NA	NA	NA	NA
Borecky et al./2008 [42]	NA	NA	NA	NA	12 mm	LT	NA	Irregular	NA	Pos.
	NA	NA	NA	NA	40 mm	LUIQ	NA	Ill defined	NA	Pos.
	NA	NA	NA	NA	17 mm	NA	Oval	Well defined	NA	Pos.
Tiu et al./2006 [43]	NA	NA	M	Neg.	13 mm	LUOQ	NA	Well defined	Increased	NA
Shin et al./2006 [44]	NA	NA	M	Neg.	12.3 mm	RUIQ	Oval	Well defined	Pos.	Pos.
Blanco et al./2005 [45]	NA	NA	NA	NA	17.5 mm	RT	Round	Well defined	NA	Pos.
Abite et al./2005 [46]	NA	Firm	M	Neg.	34.2 mm	RUOQ	NA	Well defined	NA	NA
Stafyla et al./2004 [47]	NA	NA	M	Neg.	34 mm	RUOQ	NA	Well defined	NA	NA
Abe et al./ 2004 [48]	NA	Firm	NA	Neg.	47.4 mm	LUOQ	Irregular	Well defined	NA	Neg.
Adelekan et al./2003 [49]	NA, NA	NA, NA	NA, NA	NA, NA	35 mm, 60 mm	NA, LUIQ	NA, NA	NA, NA	NA, NA	NA, NA
Yano et al./2001 [50]	Smooth	Hard	M	Neg.	18.8 mm	LUIQ	NA	Well defined	Minimal	Neg.
Gebrim et al./2000 [51]	NA	NA	M	Neg.	24.5 mm	LT	NA	Well defined	NA	Neg.
Psarianos et al./1998 [52]	NA	Firm	M	NA	29.7 mm	RUIQ	NA	Well defined	NA	NA
Shah et al./ 1998 [53]	NA	Firm	M	Neg.	22.4 mm	RUIQ	NA	Well defined	NA	NA
Kurosum et al./1994 [54]	NA	Rubbery	NA	Neg.	22.9 mm	RUOQ	NA	Well defined	NA	NA
Morimoto et al./1993 [55]	NA	Rubbery	M	NA	24.5 mm	LUIQ	NA	Well defined	NA	NA
Gupta et al./1992 [56]	NA	Firm	NA	NA	19.4 mm	LT	NA	NA	NA	NA
Gupta et al./1991 [57]	NA	Rubbery	NA	NA	NA	LUOQ	NA	NA	NA	NA
Fukud et al./1989 [58]	Smooth	NA	NA	NA	39.2 mm	ROA	NA	NA	NA	Neg.
Yoshida et al./1985 [59]	Smooth	Firm	PM	Neg.	34.1 mm	LUOQ	NA	Well defined	High	Neg.
Fond et al./1979 [60]	NA	NA	M	NA	20 mm	RSA	NA	NA	NA	NA
	NA	NA	NA	NA	20 mm	RUOQ	NA	NA	NA	Pos.
	NA	NA	NA	NA	50 mm	LUOQ	NA	NA	NA	NA
Konakry et a./1975 [61]	NA	NA	NA	NA	20 mm	LUOQ	NA	NA	NA	NA
	NA	NA	NA	NA	8 mm	RUOQ	NA	NA	NA	NA
	NA	NA	NA	NA	31.1 mm	LUOQ	NA	NA	NA	NA
Durso et al./1972 [62]	Smooth	NA	NA	NA	15 mm	RUIQ	NA	NA	NA	NA

N/A: Non-available, mm: Millimeters, Ax LAD: Axillary Lymphadenopathy, RUA: Right Upper Aspect, LLA: Left Lower Aspect, LT: Left, RT: Right, ROA: Right Outer Aspect, LUIQ: Left Upper Inner Quadrant, RLOQ: Right Lower Outer Quadrant, LUOQ: Left Upper Outer Quadrant, RLIQ: Right Lower Inner Quadrant, LIA: Left Inner Aspect, LOA: Left Outer Aspect, RUOQ: Right Upper Outer Quadrant, RRA: Right Retro-Areolar, BL: Bilateral, RLA: Right Lower Aspect, LRA: Left Retro-Areolar, LLOQ: Left Lower Outer Quadrant, LUA: Left Upper Aspect, RIA: Right Inner Aspect, RUIQ: Right Upper Inner Quadrant, RSA: Right Subareolar Area, Neg.: Negative, Pos.: Positive, NM: Non-Mobile, M: Mobile, PM: Partially mobile.

transformations from benign fibroadenomas by highlighting differences in vascularity. Benign fibroadenomas typically appear as round or oval masses with smooth margins on MRI, showing consistent enhancement into the late phase. In contrast, malignant lesions often display rapid early enhancement with variability in delayed enhancement, a hallmark of carcinoma [3]. Detecting malignant transformation can be particularly

challenging, as clinical and radiological signs may remain masked until the tumor breaches the false capsule. As a result, definitive diagnosis is usually made through histopathological examination, emphasizing the importance of maintaining a high index of suspicion in these cases [3,4]. In the present study, of the 22 cases that reported tumor shape on imaging, 15 (68.2%) presented with an oval shape, while two cases (9.1%) showed an

Table 4. Summary of radiology and biopsy findings.

First Author. /Year	Radiological findings			Pre-operative diagnosis (CNB or FNAC)
	U/S	MMG	MRI	
Ni et al./2023 [14]	Benign	Benign	Suspicious	N/A
Brunetti et al./2023 [4]	Suspicious	Benign	N/A	DCIS
Wang et al./2022 [5]	Benign	N/A	N/A	Benign
Pang et al./2022 [2]	Benign	Benign	N/A	Benign
Hammood et al./2022 [3]	Benign	Benign	Benign	Benign
Tagliati et al./2021 [1]	Benign	N/A	Suspicious	Benign
Shojaku et al./2021 [6]	Benign	Benign	Suspicious	Malignant
Fujimoto et al./2021 [11]	Suspicious	Suspicious	Benign	IDC
Feijó et al./2021[8]	Benign	N/A	N/A	Suspicious
Shiino et al./2020 [12]	Suspicious	Suspicious	Suspicious	IDC
Moreno et al./2020 [17]	N/A	N/A	N/A	N/A
Gonthong et al./2020 [13]	Suspicious	Suspicious	Suspicious	DCIS
El-Essawy et al./2020 [18]	Suspicious	Suspicious	Suspicious	DCIS
Brock et al./2020 [9]	Benign	Benign	N/A	Benign
Marumoto et al./2019 [16]	Suspicious	Benign	N/A	Benign
Zeeshan et al./2018 [19]	Suspicious	Suspicious	N/A	Benign
Tiwari et al./2018 [15]	Benign	N/A	N/A	Benign
Frisch et al./2018 [7]	Benign	N/A	N/A	N/A
Lim et al./2017 [20]	N/A	N/A	N/A	N/A
You et al./2016 [21]	Suspicious	Suspicious	N/A	Suspicious
Zheng et al./2015 [22]	Suspicious, Benign	N/A, N/A	N/A, N/A	N/A, N/A
Hua et al./2015 [23]	Suspicious	Suspicious	N/A	Benign
	N/A	N/A	N/A	N/A
	N/A	N/A	N/A	N/A
Wu et al./2014 [24]	N/A	N/A	N/A	N/A
	N/A	N/A	N/A	N/A
	N/A	N/A	N/A	N/A
	N/A	N/A	N/A	N/A
Mele et al./2014 [25]	Benign	Suspicious	Suspicious	IAC
Limite et al./2014 [26]	Benign	N/A	N/A	N/A
Kwon et al./2014 [27]	Benign, Benign	N/A, N/A	N/A, N/A	Benign, Benign
Kılıç et al./2014 [28]	Benign	Suspicious	Benign	DCIS
Dandin et al./2014 [29]	Suspicious	N/A	N/A	N/A
Buteau et al./2014 [30]	N/A	Benign	Benign	Benign
Hayes et al./2013 [31]	N/A	Suspicious	N/A	Benign
Jahan et al./2012 [32]	Benign, Benign	N/A, N/A	N/A, N/A	N/A, N/A
Butler et al./2012 [33]	Benign	Benign	N/A	ILC – LCIS
Ooe et al./2011 [34]	Suspicious	Benign	Suspicious	DCIS
Lin et al./2011 [35]	Benign	Suspicious	N/A	IDC - DCIS
Kato et al./2011 [36]	Suspicious	Suspicious	Suspicious	DCIS
Abu-Rahmeh et al./ 2012 [37]	Benign	Benign	N/A	IDC
Rao et al./ 2010 [38]	Benign	Benign	N/A	Malignant
Petersson et al./2010 [39]	N/A	Benign	N/A	N/A
Tajima et al./2009 [40]	Suspicious	Suspicious	Suspicious	Malignant
Gashi-Luci et al./2009 [41]	Suspicious	Suspicious	N/A	Benign

Table 4. Continued....

	Suspicious	Suspicious	N/A	IDC - DCIS
Borecky et al./2008 [42]	Suspicious	Suspicious	N/A	IC
	Suspicious	Suspicious	N/A	IDC - DCIS
Tiu et al./2006 [43]	Benign	Benign	N/A	Malignant
Shin et al./2006 [44]	Suspicious	Suspicious	Suspicious	DCIS
Blanco et al./2005 [45]	N/A	Benign	N/A	N/A
Abite et al./2005 [46]	N/A	N/A	N/A	N/A
Stafyla et al./2004 [47]	Benign	N/A	N/A	N/A
Abe et al./ 2004 [48]	Suspicious	Benign	N/A	Benign
Adelekan et al./2003 [49]	N/A, N/A	Benign, Benign	N/A, N/A	Benign, Malignant
Yano et al./2001 [50]	Benign	Suspicious	Benign	Malignant
Gebirim et al./2000 [51]	N/A	Suspicious	N/A	Benign
Psarianos et al./1998 [52]	Benign	Benign	N/A	N/A
Shah et al./ 1998 [53]	N/A	Benign	N/A	Benign
Kurosum et al./1994 [54]	Benign	N/A	N/A	N/A
Morimoto et al./1993 [55]	N/A	N/A	N/A	Benign
Gupta et al./1992 [56]	N/A	Suspicious	N/A	Malignant
Gupta et al./1991 [57]	N/A	Benign	N/A	Malignant
Fukud et al./1989 [58]	Benign	Benign	N/A	N/A
Yoshida et al./1985 [59]	N/A	Suspicious	Suspicious	N/A
Fond et al./1979 [60]	N/A	N/A	N/A	Benign
	N/A	Suspicious	N/A	N/A
	N/A	Benign	N/A	N/A
Konakry et a./1975 [61]	N/A	Benign	N/A	N/A
	N/A	Benign	N/A	N/A
	N/A	Benign	N/A	N/A
Durso et al./1972 [62]	N/A	Benign	N/A	N/A

N/A: non-available, U/S: Ultrasound, MMG: Mammogram, MRI: Magnetic Resonance Imaging, CNB: Core Needle Biopsy, FNAC: Fine Needle Aspiration Cytology, DCIS: Ductal Carcinoma In Situ, IDC: Invasive Ductal Carcinoma, CIS: Carcinoma In Situ, IAC: Invasive apocrine carcinoma, ILC: Invasive Lobular Carcinoma, LCIS: Lobular Carcinoma In Suspicious, IC: Invasive Carcinoma.

irregular shape. Tumor margins were well-defined in 32 out of 47 margins. Among the 10 cases reporting tumor vascularity, eight (80%) showed increased or high vascularity. Calcifications were observed in 24 out of 35 cases (68.6%) that provided data on this feature.

Common clinical techniques for obtaining pathological information include FNAC, hollow CNB, and mass excision biopsy. However, due to the inherent heterogeneity of these lesions, FNAC and CNB may not always provide conclusive results to definitively exclude malignancy in benign breast lesions that carry an increased risk of cancer development. Consequently, an open biopsy is recommended as a more reliable method for accurate diagnosis [15]. If imaging studies of a fibroadenoma indicate enlargement or any abnormal changes during follow-up examinations, it is essential to perform a CNB to ensure a definitive assessment. For patients aged 40 years and older with clinically benign fibroadenomas, clinicians should engage in discussions with these patients regarding the potential necessity of a CNB. This proactive approach allows for a thorough evaluation of changes and

ensures appropriate diagnostic measures are implemented [12]. The diagnosis of fibroadenoma with carcinoma in the breast is contingent upon several critical criteria. Firstly, there must be clear evidence of epithelial heterogeneous hyperplasia or carcinoma within the fibroadenoma. Secondly, the cancerous tissue should remain confined to the capsule of the fibroadenoma, with only minimal focal infiltration into the surrounding breast tissue. Thirdly, it is crucial to exclude the possibility of infiltration from adjacent breast cancer into the fibroadenoma, as the coexistence of breast cancer and fibroadenoma does not qualify as intra-fibroadenoma carcinoma. Finally, the diagnosis must be supported by the results of immunohistochemical markers. These criteria facilitate a thorough and accurate assessment of fibroadenoma with carcinoma [15]. In this systematic review, pre-operative tissue biopsy using either CNB or FNAC was available for 46 tumors. Malignant features were observed in 24 tumors (52.2%), two tumors (4.3%) exhibited suspicious features, and 20 tumors (43.5%) were classified as benign. These findings highlight the importance of pre-operative biopsy and the challenges in

Table 5. Breast carcinoma management strategies

First Author /Year	Management				Hormonal therapy
	Breast surgery	Axillary surgery	Chemotherapy	Radiotherapy	
Ni et al./2023 [14]	WLE	SLNB	No	No	NA
Brunetti et al./2023 [4]	WLE	ALND	Yes	NA	NA
Wang et al./2022 [5]	EB	None	NA	Yes	Yes
Pang et al./2022 [2]	WLE	None	No	NA	Yes
Hammood et al./2022 [3]	WLE	None	NA	NA	Yes
Tagliati et al./2021 [1]	WLE	None	NA	No	NA
Shojaku et al./2021 [6]	WLE	SLNB	NA	Yes	NA
Fujimoto et al./2021 [11]	WLE	SLNB	Yes	Yes	NA
Feijó et al./2021[8]	WLE	None	Yes	Yes	NA
Shiino et al./2020 [12]	MX	ALND	Yes	Yes	NA
Moreno et al./2020 [17]	MX	None	NA	NA	NA
Gonthong et al./2020 [13]	MX	ALND	No	No	Yes
El-Essawy et al./2020 [18]	WLE	None	NA	NA	NA
Brock et al./2020 [9]	WLE	None	NA	NA	NA
Marumoto et al./2019 [16]	EB	None	No	Yes	Yes
Zeeshan et al./2018 [19]	WLE	None	NA	Yes	Yes
Tiwari et al./2018 [15]	WLE	None	No	No	NA
Frisch et al./2018 [7]	WLE	NA	NA	No	Yes
Lim et al./2017 [20]	WLE	None	No	No	No
You et al./2016 [21]	WLE	None	NA	NA	Yes
Zheng et al./2015 [22]	MX	ALND	Yes	NA	Yes
Hua et al./2015 [23]	MX	None	NA	NA	Yes
Wu et al./2014 [24]	WLE	SLNB	No	No	Yes
	MX	ALND	Yes	No	Yes
	WLE	NA	No	No	Yes
	WLE	SLNB	No	Yes	Yes
	WLE	SLNB	No	No	No
Mele et al./2014 [25]	MX	SLNB	No	No	Yes
	MRM	ALND	NA	NA	NA
	WLE	SLNB	No	No	NA
	WLE	None	NA	Yes	NA
	WLE	None	NA	NA	NA
Dandin et al./2014 [29]	WLE	ALND	Yes	NA	NA
Buteau et al./2014 [30]	WLE	ALND	Yes	Yes	Yes
Hayes et al./2013 [31]	WLE	SLNB	NA	NA	NA
Jahan et al./2012 [32]	WLE	None	NA	NA	NA
Butler et al./2012 [33]	WLE	None	NA	NA	NA
Ooe et al./2011 [34]	WLE	SLNB	No	Yes	Yes
Lin et al./2011 [35]	MRM	None	NA	NA	NA
Kato et al./2011 [36]	WLE	SLNB	NA	NA	NA
Abu-Rahmeh et al./ 2012 [37]	NA	NA	NA	NA	NA
Rao et al./ 2010 [38]	MRM	ALND	NA	NA	NA
Petersson et al./2010 [39]	EB	SLNB	NA	NA	NA
Tajima et al./2009 [40]	WLE	None	NA	NA	NA
Gashi-Luci et al./2009 [41]	RM	ALND	NA	NA	NA

Table 5. Continued....

	NA	NA	NA	NA	NA
Borecky et al./2008 [42]	NA	NA	NA	NA	NA
	EB	SLNB	NA	NA	NA
Tiu et al./2006 [43]	MX	None	NA	NA	NA
Shin et al./2006 [44]	MX	SLNB	NA	NA	NA
Blanco et al./2005 [45]	WLE	SLNB	NA	NA	NA
Abite et al./2005 [46]	EB	None	NA	NA	NA
Stafyla et al./2004 [47]	EB	None	No	No	NA
Abe et al./ 2004 [48]	MX	ALND	Yes	NA	Yes
Adelekan et al./2003 [49]	EB, MRM	None, ALND	Yes	Yes	Yes
Yano et al./2001 [50]	WLE	ALND	NA	Yes	NA
Gebrim et al./2000 [51]	MX	ALND	NA	NA	NA
Psarianos et al./1998 [52]	EB	None	NA	NA	NA
Shah et al./ 1998 [53]	WLE	NA	NA	NA	NA
Kurosum et al./1994 [54]	WLE	None	NA	Yes	NA
Morimoto et al./1993 [55]	WLE	None	Yes	NA	NA
Gupta et al./1992 [56]	WLE	None	NA	Yes	Yes
Gupta et al./1991 [57]	WLE	ALND	NA	Yes	NA
Fukud et al./1989 [58]	MRM	NA	NA	NA	NA
Yoshida et al./1985 [59]	RM	ALND	No	No	NA
Fond et al./1979 [60]	MRM	ALND	NA	NA	NA
	RM	NA	NA	NA	NA
	MRM	NA	NA	NA	NA
Konakry et a./1975 [61]	MRM	NA	NA	NA	NA
	MX	NA	NA	NA	NA
	MRM	NA	NA	NA	NA
Durso et al./1972 [62]	EB	None	NA	NA	NA

NA: non-available, WLE: Wide Local Excision, EB: Excisional Biopsy, RM: Radical Mastectomy, MRM: Modified Radical Mastectomy, MX: Mastectomy, ALND: Axillary Lymph Node Dissection, SLNB: Sentinel Lymph Node Biopsy.

accurately identifying the presence of malignancy in fibroadenomas.

Given the rarity of malignancy arising within fibroadenomas, standardized management guidelines are not well-established, leaving uncertainty as to whether these patients should be treated similarly to breast cancer patients or with a distinct approach. For benign fibroadenomas, lumpectomy remains the treatment of choice. However, if the tumor is close to or involves the resection margin, wider local excision may be necessary to ensure complete removal. Factors such as large tumor size, multifocality, and central breast location may also necessitate consideration of mastectomy [3,4,16]. If surgical margins are free of cancer, lumpectomy alone is often sufficient. The overall management strategy is dictated by the stage of the disease and the degree of metastasis, whether localized or distant. Conservative management, such as lumpectomy or wide local excision, is usually appropriate for small tumors. In cases of local metastasis, especially involving the axillary lymph nodes, axillary lymph node dissection is typically performed to ensure proper treatment [3]. Surgical intervention remains the definitive treatment and may be combined with radiotherapy or chemotherapy depending on individual case specifics [16]. In the current study, the most common procedure was wide local

excision (50.7%), followed by mastectomy (32.9%). Excisional biopsy was performed in 12.3% of the cases. Axillary lymph node dissection was performed in 17 cases (23.3%), while sentinel lymph node biopsy was carried out in 15 cases (20.6%). Twenty-nine cases (39.7%) did not undergo axillary surgery. This variation in axillary management highlights the individualized approach to surgical treatment based on tumor characteristics, lymph node involvement, and disease progression.

The use of radiotherapy remains a topic of debate, with chemotherapy being the preferred treatment option in cases involving nodal metastasis. Some authors suggested that breast cancer arising within a fibroadenoma exhibits similar behavior to breast cancer at the same stage. Consequently, the treatment approach should align with standard breast cancer protocols, following similar therapeutic modalities [4,5,11,17]. The positive impact of radiation therapy on both survival rates and recurrence prevention when combined with lumpectomy has been reported. This approach is regarded as the standard of care for breast-conserving therapy in cases of DCIS and breast cancer. However, radiation therapy is not without drawbacks. It carries inherent risks, financial costs, and potential negative effects on patients' quality of life. Notably, long-term

Table 6. Clinical outcomes of the disease.

First Author /Year	Post-operative HPE	Immunohistochemistry (ER-PR-HER2)	Axillary status	FU (months)	Recurrence	Metastasis
Ni et al./2023 [14]	DCIS	ER - PR	Neg.	NA	NA	No
Brunetti et al./2023 [4]	IDC	TN	Pos.	NA	NA	Yes
Wang et al./2022 [5]	ILC - LCIS	ER - PR	NA	NA	NA	NA
Pang et al./2022 [2]	LCIS	NA	NA	4	No	No
Hammood et al./2022 [3]	DCIS	NA	NA	NA	No	No
Tagliati et al./2021 [1]	DCIS	ER - PR	NA	60	No	No
Shojaku et al./2021 [6]	DCIS	ER	NA	24	No	No
Fujimoto et al./2021 [11]	IDC	HER2	Neg.	6	No	No
Feijó et al./2021[8]	DCIS	ER - PR	NA	48	No	No
Shiino et al./2020 [12]	IDC	TN	Neg.	30	No	No
Moreno et al./2020 [17]	LCIS	NA	NA	120	No	No
Gonthong et al./2020 [13]	DCIS	TN	Neg.	12	No	No
El-Essawy et al./2020 [18]	NA	TN	NA	NA	NA	NA
Brock et al./2020 [9]	LCIS	NA	NA	NA	NA	NA
Marumoto et al./2019 [16]	DCIS	ER	NA	12	No	No
Zeeshan et al./2018 [19]	DCIS	ER - PR	NA	NA	NA	No
Tiwari et al./2018 [15]	DCIS	NA	NA	12	No	No
Frisch et al./2018 [7]	DCIS	ER	NA	NA	NA	No
Lim et al./2017 [20]	CA	TN	NA	21	No	No
You et al./2016 [21]	DCIS	ER - PR	NA	52	No	No
Zheng et al./2015 [22]	ILC, IDC	HER2, ER-PR-HER2	Neg., Neg.	3	No	No
Hua et al./2015 [23]	LCIS	ER - PR	NA	60	No	No
	IDC	ER - PR	Neg.	NA	NA	NA
	IDC	ER - PR	Pos.	NA	NA	NA
Wu et al./2014 [24]	DCIS	ER - PR	NA	NA	NA	NA
	DCIS	ER - PR	Neg.	NA	NA	NA
	DCIS	NA	Neg.	NA	NA	NA
	IDC	ER - PR	Neg.	NA	NA	NA
Mele et al./2014 [25]	IAC	HER2	Pos.	NA	NA	NA
Limite et al./2014 [26]	ACC (Ac)	TN	Neg.	8	No	No
Kwon et al./2014 [27]	DCIS, DCIS	ER - PR, ER - PR	NA, NA	NA, NA	NA	NA
Kılıç et al./2014 [28]	DCIS	NA	NA	NA	NA	NA
Dandin et al./2014 [29]	IDC - ILC - DCIS	PR - HER2	Neg.	6	No	No
Buteau et al./2014 [30]	ILC	NA	Pos.	NA	No	No
Hayes et al./2013 [31]	ILC	ER	Neg.	NA	NA	NA
Jahan et al./2012 [32]	IDC, IDC	NA, NA	NA, NA	NA, NA	NA	NA
Butler et al./2012 [33]	ILC - LCIS	NA	NA	NA	NA	NA
Ooe et al./2011 [34]	DCIS	ER - PR	Neg.	6	No	No
Lin et al./2011 [35]	IDC - DCIS	ER - PR	NA	24	No	No
Kato et al./2011 [36]	DCIS	NA	Neg.	NA	NA	NA
Abu-Rahmeh et al./ 2012 [37]	IDC	NA	NA	NA	NA	Yes
Rao et al./ 2010 [38]	IDC	TN	Pos.	NA	NA	NA
Petersson et al./2010 [39]	IDC - DCIS	ER - PR	Neg.	24	No	No
Tajima et al./2009 [40]	ILC - LCIS	ER	NA	NA	NA	NA
Gashi-Luci et al./2009 [41]	IDC - DCIS	HER2	Neg.	5	Yes	NA

Table 6. Continued....

	IDC - DCIS	ER – PR	Neg.	NA	NA	NA
Borecky et al./2008 [42]	IDC	NA	Neg.	NA	NA	NA
	IDC - DCIS	NA	Neg.	NA	NA	NA
Tiu et al./2006 [43]	DCIS	NA	NA	18	No	No
Shin et al./2006 [44]	IDC - DCIS	ER – PR	Neg.	16	No	No
Blanco et al./2005 [45]	ACC (Ad)	TN	Neg.	NA	NA	NA
Abite et al./2005 [46]	IDC	NA	NA	NA	NA	NA
Stafyla et al./2004 [47]	LCIS	NA	NA	24	No	No
Abe et al./ 2004 [48]	IDC	PR	Pos.	59	No	No
Adelekan et al./2003 [49]	IC, LCIS - DCIS	NA, NA	NA, Pos.	NA, NA	NA	No
Yano et al./2001 [50]	LCIS	NA	Neg.	24	No	No
Gebirim et al./2000 [51]	ILC	NA	Neg.	NA	No	No
Psarianos et al./1998 [52]	DCIS	NA	NA	NA	NA	NA
Shah et al./ 1998 [53]	LCIS	NA	NA	25	No	No
Kurosum et al./1994 [54]	IDC	NA	NA	NA	NA	No
Morimoto et al./1993 [55]	LCIS	NA	NA	132	No	No
Gupta et al./1992 [56]	DCIS	NA	NA	9	No	No
Gupta et al./1991 [57]	CA	NA	Neg.	10	No	No
Fukud et al./1989 [58]	LCIS	NA	NA	NA	No	No
Yoshida et al./1985 [59]	ILC	ER	Neg.	32	No	No
Fond et al./1979 [60]	DCIS	NA	Neg.	NA	NA	NA
	LCIS	NA	Neg.	60	No	No
	LCIS	NA	Neg.	36	No	No
Konakry et a./1975 [61]	LCIS	NA	Neg.	36	No	No
	LCIS	NA	Neg.	24	No	No
	LCIS	NA	Neg.	NA	No	No
Durso et al./1972 [62]	LCIS	NA	NA	NA	NA	NA

NA: non-available, DCIS: Ductal Carcinoma In Situ, IDC: Invasive Ductal Carcinoma, CIS: Carcinoma In Situ, IAC: Invasive apocrine LCIS - DCIScarcinoma, ILC: Invasive Lobular Carcinoma, LCIS: Lobular Carcinoma In Suspicious, ACC (ac): Acinic Cell Carcinoma, ACC (Ad): Adenoid Cystic Carcinoma, IC: Invasive Carcinoma, CA: Carcinoma, ER: Estrogen Receptor, PR: Progesterone Receptor, HER2: Human Epidermal Growth Factor Receptor 2, TN: Triple Negative, HPE: Histopathological Examination, Pos.: positive, Neg.: negative, FU: Follow-up.

complications such as lung cancer and heart disease have been associated with breast cancer radiation therapy, particularly in patients who have a history of smoking [17]. Ni et al. stated that DCIS within a fibroadenoma is a heterogeneous condition with significant variability in local recurrence risks among patients. Consequently, the overall benefits of postoperative radiation therapy differ based on individual patient risk profiles. Low-risk patients who undergo breast-conserving surgery (BCS) without subsequent radiotherapy experience limited advantages from radiation. In contrast, high-risk patients show a greater benefit from the addition of radiotherapy. For instance, it has been revealed that patients treated with BCS alone had 8-year recurrence rates of 0%, 21.5%, and 32.1% for low-, intermediate-, and high-risk groups, respectively. This highlights the need for personalized treatment approaches based on risk stratification [15]. The current National Comprehensive Cancer Network (NCCN) guidelines recommend ER testing for patients with DCIS and advise considering tamoxifen for

women with ER-positive disease, particularly those who undergo BCS without radiation. The goal is to optimize treatment outcomes and minimize the chances of cancer recurrence [7]. In this study, the data on chemotherapy was available for only 26 cases, of which 11 (42.3%) underwent chemotherapy as part of their treatment regimen. Additionally, among 30 cases with information on radiation therapy, 16 cases (53.3%) received the treatment regimen. Furthermore, 22 cases addressed hormonal therapy, and 20 (90.9%) indicated it was utilized in the treatment protocols.

Some scholars indicated that breast cancer developing within a fibroadenoma is generally associated with a more favorable prognosis compared to conventional breast cancer. This is primarily attributed to the higher incidence of hormone receptor (HR)-positive tumors in this subset, along with the frequent presentation of CIS and early-stage disease at diagnosis [12]. However, the prevalence of hormone receptor positivity in these

Table 7. Baseline characteristics summary of the included studies.

Variables	Frequency/ percentages
Study design	
Case report	58 (95.0%)
Case series	3 (5.0 %)
Country	
Japan	12 (19.7%)
USA	9 (14.7%)
Korea	4 (6.6%)
Brazil	3 (4.9%)
China	3 (4.9%)
Italy	3 (4.9%)
Taiwan	3 (4.9%)
Australia	2 (3.3%)
India	2 (3.3%)
New Zealand	2 (3.3%)
Singapore	2 (3.3%)
Turkey	2 (3.3%)
Others	14 (22.9%)
Age range (mean ± SD)	18-80 (44.4 ± 13.6)
Gender	
Female	72 (100%)
Presentation	
Lump	31 (43.1%)
Mass	22 (30.5%)
Incidental	3 (4.1%)
Nodule	2 (2.8%)
Nipple discharge	1 (1.4%)
N/A	13 (18.1%)
Duration of presentation, median (Q1 - Q3), months	12 (2-60)
Laterality	
Unilateral	58 (80.6%)
Bilateral	6 (8.3%)
N/A	8 (11.1%)
Tumor location	
Right	32 (42.1%)
Left	30 (39.5%)
Bilateral	1 (1.3%)
N/A	13 (17.1%)
Tumor size (mean ± SD), mm	24.7 ± 13.3
PMH	
Nothing noteworthy	20 (27.8%)
Breast mass	4 (5.5%)
Hypertension	1 (1.4%)
CAH	1 (1.4%)
DCIS	1 (1.4%)
Fibrocystic breast disease	1 (1.4%)

Table 7. Continued....

IDC	1 (1.4%)
N/A	43 (59.7%)
Family history of breast cancer	
Positive	4 (5.5%)
Negative	31 (43.1%)
N/A	37 (51.4%)
Surface of the mass	
Smooth	9 (11.8%)
N/A	67 (88.2%)
Consistency of the mass	
Firm	14 (18.4%)
Hard	5 (6.6%)
Rubbery	3 (3.9%)
N/A	54 (71.1%)
Mobility of the mass	
Mobile	25 (32.9%)
Non-mobile	2 (2.6%)
Partially fixed	1 (1.3%)
N/A	48 (63.2%)
Axillary Lymphadenopathy	
Negative	27 (35.5%)
Positive	4 (5.3%)
N/A	45 (59.2%)
Radiological findings	
Ultrasonography	
Benign	28 (36.8%)
Suspicious	20 (26.3%)
N/A	28 (36.8%)
Mammography	
Benign	27 (35.5%)
Suspicious	23 (30.3%)
N/A	26 (34.2%)
Magnetic resonance imaging	
Suspicious	12 (15.8%)
Benign	5 (6.6%)
N/A	59 (77.6%)
Shape of the mass	
Oval	15 (19.7%)
Irregular	2 (2.6%)
Lobular	2 (2.6%)
Round	2 (2.6%)
Multilobulated	1 (1.3%)
N/A	54 (71.1%)
Margin of the mass	
Well defined	32 (42.1%)
Irregular	7 (9.2%)
Ill-defined	4 (5.3%)

Table 7. Continued....

Lobulated	3 (4%)
Smooth	2 (2.6%)
Microlobulated	1 (1.3%)
Circumscribed	1 (1.3%)
N/A	26 (34.2%)
Vascularity of the mass	
Yes	8 (10.5%)
No	2 (2.6%)
N/A	66 (86.8%)
Calcification	
Positive	24 (31.6%)
Negative	11 (14.5%)
N/A	41 (53.9%)
Cytology (CNB or FNAC)	
Benign	20 (26.3%)
Malignant (non-specified)	8 (10.5%)
DCIS	7 (9.2%)
IDC	3 (4%)
IDC – DCIS	3 (4%)
Suspicious	2 (2.6%)
IC	1 (1.3%)
ILC – LCIS	1 (1.3%)
Invasive apocrine carcinoma	1 (1.3%)
N/A	30 (39.5%)
Breast surgery	
Wide local excision	37 (50.7%)
Mastectomy	24 (32.9%)
Excisional biopsy	9 (12.3%)
N/A	3 (4.1%)
Axillary surgery	
ALND	17 (23.3%)
SLNB	15 (20.6%)
None	29 (39.7%)
N/A	12 (16.4%)
Chemotherapy	
Yes	11 (15.3%)
No	15 (20.8%)
NA	46 (63.9%)
Radiation therapy	
Yes	16 (22.2%)
No	14 (19.4%)
NA	42 (58.3%)
Hormonal therapy	
Yes	20 (27.8%)
No	2 (2.8%)
NA	50 (69.4%)
Post-operative HPE	

Table 7. Continued....

DCIS	23 (30.3%)
LCIS	15 (19.7%)
IDC	15 (19.7%)
IDC - DCIS	6 (7.9%)
ILC	5 (6.6%)
ILC - LCIS	3 (4%)
Carcinoma (non-specified)	3 (4%)
Acinic cell carcinoma	1 (1.3%)
Adenoid cystic carcinoma	1 (1.3%)
IDC - ILC - DCIS	1 (1.3%)
Invasive apocrine carcinoma	1 (1.3%)
LCIS – DCIS	1 (1.3%)
N/A	1 (1.3%)
Immunohistochemistry	
ER – PR	19 (25%)
Triple-negative	8 (10.5%)
ER	6 (7.9%)
HER2	4 (5.3%)
ER - PR - HER2	1 (1.3%)
PR - HER2	1 (1.3%)
PR	1 (1.3%)
N/A	36 (47.4%)
Axillary status	
Positive	7 (9.2%)
Negative	32 (42.1%)
N/A	37 (48.7%)
Follow-up, median (Q1-Q3), months	24 (10-36)
Recurrence	
No	38 (52.8%)
Yes	1 (1.4%)
N/A	33 (45.8%)
Metastasis	
No	43 (59.7%)
Yes	2 (2.8%)
N/A	27 (37.5%)

SD: Standard Deviation, N/A: non-available, CAH: Congenital Adrenal Hyperplasia, DCIS: Ductal Carcinoma In Situ, IDC: Invasive Ductal Carcinoma, CNB: Core Needle Biopsy, FNAC: Fine Needle Aspiration Cytology, CIS: Carcinoma In Situ, IC: Invasive Carcinoma, ILC: Invasive Lobular Carcinoma, LCIS: Lobular Carcinoma In Situ, ALND: Axillary Lymph Node Dissection, SLNB: Sentinel Lymph Node Biopsy, HPE: Histopathological Examination, ER: Estrogen Receptor, PR: Progesterone Receptor, HER2: Human Epidermal Growth Factor Receptor 2, Q1: first quartile, Q3: third quartile, PMH: past medical history.

cases may not significantly differ from that seen in typical breast cancer. ER positivity has been reported at 68.8%, and PR positivity at 62.5%, figures closely aligned with those observed in conventional breast cancer [11]. Despite these favorable characteristics, it has been indicated that approximately 10% of patients diagnosed with CIS within a fibroadenoma experience recurrence or metastasis, emphasizing the need for continued surveillance and individualized treatment strategies, even in cases with seemingly better prognostic indicators [3]. In this systematic review, among the 40 tumors with available hormone receptor status, six (15%) were HR-positive. The ER was positive in 26 tumors (65%), and PR was positive in 22 tumors (55%). The median follow-up duration was 24 months, during which one case (1.4%) reported recurrence, and two cases (2.8%) experienced metastasis. The primary limitation of this study is the lack of data on several variables in the reviewed studies, which may impact the generalizability of the findings.

5. Conclusion

Although rare, carcinomas arising within fibroadenomas may present considerable challenges in preoperative diagnosis, whether through imaging or cytology. Therefore, clinicians may find it necessary to approach fibroadenomas with increased caution.

Declarations

Conflicts of interest: The author(s) have no conflicts of interest to disclose.

Ethical approval: Not applicable, as systematic reviews do not require ethical approval.

Patient consent (participation and publication): Not applicable.

Funding: The present study received no financial support.

Acknowledgements: None to be declared.

Authors' contributions: AMS, LRAP and SL were significant contributors to the conception of the study and the literature search for related studies. BAA, DAH, BOH, HAH, SHS, DAO, SSA and SMA were involved in the literature review, the study's design, and the critical revision of the manuscript, and they participated in data collection. MGH, MNH and HOA were involved in the literature review, study design, and manuscript writing. YMM, HAH and SSO Literature review, final approval of the manuscript, and processing of the tables. HOA and AMS confirm the authenticity of all the raw data. All authors approved the final version of the manuscript.

Use of AI: AI was not used in the drafting of the manuscript, the production of graphical elements, or the collection and analysis of data.

Data availability statement: Note applicable.

References

1. Tagliati C, Lami G, Cerimele F, et al. Low diffusion level within a fibroadenoma as the sole sign of ductal carcinoma in situ: A case report. *Breast Disease*. 2021;40(4):283-6. [doi:10.3233/bd-201080](https://doi.org/10.3233/bd-201080)
2. Pang FT, Kornecki A, Lynn K, et al. A rare case of lobular carcinoma in situ within a fibroadenoma. *Arch Breast Cancer*. 2022;119-22. [doi:10.32768/abc.202291119-122](https://doi.org/10.32768/abc.202291119-122)
3. Hammood ZD, Mohammed SH, Abdulla BA, et al. Ductal carcinoma in situ arising from fibroadenoma; a rare case with review of literature. *Ann Med Surg*. 2022;75:103-8. [doi:10.1016/j.amsu.2022.103449](https://doi.org/10.1016/j.amsu.2022.103449)
4. Brunetti N, Valente I, Pitto F, et al. Triple-negative breast cancer arising in a fibroadenoma in BRCA 1 mutated patient. *J Med Ultrasound*. 2023;31(1):63-5. [doi:10.4103/jmu.jmu.83.21](https://doi.org/10.4103/jmu.jmu.83.21)
5. Wang M, Leong MY, Tan QT. A case of fibroadenoma with lobular carcinoma in situ and microinvasion in a young woman. *J Surg Case Rep*. 2022;2022(12). [doi:10.1097/md.00000000000024023](https://doi.org/10.1097/md.00000000000024023)
6. Shojaku H, Hori R, Yoshida T, et al. Low-grade ductal carcinoma in situ (DCIS) arising in a fibroadenoma of the breast during 5 years follow-up: a case report. *Medicine*. 2021;100(10). [doi:10.1097/md.00000000000024023](https://doi.org/10.1097/md.00000000000024023)
7. Frisch O, De Jager LJ, Otto M, et al. A teenager with ductal carcinoma in situ arising in a fibroadenoma: a case report. *S Afr J Surg*. 2018;56(4):30-3. [doi:10.17159/2078-5151/2018v56n4a2766](https://doi.org/10.17159/2078-5151/2018v56n4a2766)
8. Feijó CQ, da Costa RE, da Silva Fontinele DR, et al. Low-grade carcinoma in situ in fibroadenoma: a case report. *Mastology*. 2021;31:1-3. [doi:10.29289/2594539420210058](https://doi.org/10.29289/2594539420210058)
9. Brock CM, Harper C, Tyler T. Fibroadenoma containing lobular carcinoma in situ, an unusual finding in a normally benign mass. *J Surg Case Rep*. 2020;2020(4). [doi:10.1093/jscr/rjaa059](https://doi.org/10.1093/jscr/rjaa059)
10. Abdullah HO, Abdalla BA, Kakamad FH, et al. Predatory publishing lists: A review on the ongoing battle against fraudulent actions. *Barw Med J*. 2024;1(1):45-9. [doi:10.58742/bmj.v2i2.91](https://doi.org/10.58742/bmj.v2i2.91)
11. Fujimoto A, Matsuura K, Kawasaki T, et al. Early HER2-positive breast cancer arising from a fibroadenoma: a case report. *Oxf Med Case Rep*. 2021;2021(9). [doi:10.1093/omcr/omab083](https://doi.org/10.1093/omcr/omab083)
12. Shiino S, Yoshida M, Tokura M, et al. Locally advanced triple-negative breast cancer arising from fibroadenoma with complete response to neoadjuvant chemotherapy: a case report. *Int J Surg Case Rep*. 2020;68:234-8. [doi:10.1016/j.ijscr.2020.02.059](https://doi.org/10.1016/j.ijscr.2020.02.059)
13. Gonthong A. Ductal carcinoma in situ within fibroadenoma: report of imaging features. *J Dep Med Serv*. 2021;46(2):151-8. [doi:10.2147/ott.s413223](https://doi.org/10.2147/ott.s413223)
14. Ni XH, An R, Shi QW, et al. Low-grade ductal carcinoma in situ within a fibroadenoma of the breast: A rare case report and review of the literature. *OncoTargets Ther*. 2023;16:399-406. [doi:10.2147/ott.s413223](https://doi.org/10.2147/ott.s413223)
15. Tiwari A, Singh BM, Varshney S, et al. Incidental detection of carcinoma in situ in fibroadenoma of the breast in a young woman: a rare finding. *Cureus*. 2018;10(12). [doi:10.7759/cureus.3797](https://doi.org/10.7759/cureus.3797)
16. Marumoto A, Steinemann S, Furumoto N, et al. An uncommon pairing of common tumors: case report of ductal carcinoma in situ within fibroadenoma. *Hawaii J Med Public Health*. 2019;78(2):39. [doi:10.5348/100916z01sz2018cr](https://doi.org/10.5348/100916z01sz2018cr)
17. Moreno M, Menegassi J, Neto OV, et al. Metachronous breast neoplasms: squamous cell carcinoma and lobular carcinoma in situ within a fibroadenoma. *Mastology*. 2020;30:1-4. [doi:10.29289/25945394202020200016](https://doi.org/10.29289/25945394202020200016)
18. El-Essawy M, AL Haidary A, Khan AL. Ductal carcinoma in situ (DCIS) in breast fibroadenoma. *Egypt J Radiol Nucl Med*. 2020;51:1-7. [doi:10.1186/s43055-020-00191-5](https://doi.org/10.1186/s43055-020-00191-5)
19. Zeeshan S, Siddique S, Riaz N. Ductal carcinoma in situ within fibroadenoma of the breast: a case report with literature review. *Int J Case Rep Images*. 2018;9:100916Z01SZ2018. [doi:10.5348/100916Z01SZ2018CR](https://doi.org/10.5348/100916Z01SZ2018CR)
20. Lim S, Shim MK, Cho EY, et al. Secretory carcinoma arising in a fibroadenoma: a brief case report. *J Pathol Transl Med*. 2018;52(3):198-201. [doi:10.4132/jptm.2017.08.01](https://doi.org/10.4132/jptm.2017.08.01)
21. You JK, Kim YJ, Kim B, et al. Ductal carcinoma in situ within a fibroadenoma: microcalcifications identified on mammography play a crucial role in diagnosis. *J Korean Soc Radiol*. 2016;74(6):361-4. [doi:10.3348/jksr.2016.74.6.361](https://doi.org/10.3348/jksr.2016.74.6.361)
22. Zheng H, Chen J, Wu X, et al. Bilateral breast cancer with a unilateral carcinoma within a fibroadenoma: a case report. *Oncol Lett*. 2015;10(3):1513-6. [doi:10.3892/ol.2015.3420](https://doi.org/10.3892/ol.2015.3420)
23. Hua B, Xu JY, Jiang L, et al. Fibroadenoma with an unexpected lobular carcinoma in situ: a case report and review of the literature. *Oncol Lett*. 2015;10(3):1397-401. [doi:10.3892/ol.2015.3488](https://doi.org/10.3892/ol.2015.3488)
24. Wu YT, Chen ST, Chen CJ, et al. Breast cancer arising within fibroadenoma: collective analysis of case reports in the literature and hints on treatment policy. *World J Surg Oncol*. 2014;12:335. [doi:10.1186/1477-7819-12-335](https://doi.org/10.1186/1477-7819-12-335)
25. Mele M, Vahl P, Funder JA, et al. Apocrine carcinoma arising in a complex fibroadenoma: a case report. *Breast Dis*. 2014;34(4):183-7. [doi:10.3233/bd-140365](https://doi.org/10.3233/bd-140365)

26. Limite G, Di Micco R, Esposito E, et al. The first case of acinic cell carcinoma of the breast within a fibroadenoma: case report. *Int J Surg*. 2014;12. [doi:10.1016/j.ijsu.2014.05.005](https://doi.org/10.1016/j.ijsu.2014.05.005)
27. Kwon MJ, Park HR, Seo J, et al. Simultaneous occurrence of ductal carcinoma in situ within juvenile fibroadenoma in both breasts: a brief case report. *Korean J Pathol*. 2014;48(2):164. [doi:10.4132/koreanjpathol.2014.48.2.164](https://doi.org/10.4132/koreanjpathol.2014.48.2.164)
28. Kılıç F, Ustabasıoğlu FE, Samancı C, et al. Ductal carcinoma in situ detected by shear wave elastography within a fibroadenoma. *J Breast Cancer*. 2014;17(2):180. [doi:10.4048/jbc.2014.17.2.180](https://doi.org/10.4048/jbc.2014.17.2.180)
29. Dandin Ö, Karakaş DÖ, Balta AZ, et al. Invasive breast carcinoma occurring within fibroadenoma: case report. *Türkiye Klinikleri J Case Rep*. 2015;23(2):149-52. [doi:10.5336/caserep.2013-37780](https://doi.org/10.5336/caserep.2013-37780)
30. Buteau AH, Waters RE, Boroumand N. Metastatic carcinoma arising from fibroadenoma of the breast. *Int J Cancer Oncol*. 2014;1:1-3. [doi:10.1177/1066896912471854](https://doi.org/10.1177/1066896912471854)
31. Hayes BD, Quinn CM. Microinvasive lobular carcinoma arising in a fibroadenoma. *Int J Surg Pathol*. 2013;21(4):419-21. [doi:10.1177/1066896912471854](https://doi.org/10.1177/1066896912471854)
32. Jahan F, Ghosh PK, Rahman S, et al. Fibroadenoma with foci of infiltrating ductal carcinoma. *J Med*. 2012;13(1):115. [doi:10.3329/jom.v13i1.10088](https://doi.org/10.3329/jom.v13i1.10088)
33. Butler R, Pinsky R, Jorns JM, et al. Alveolar variant of invasive lobular carcinoma in a fibroadenoma. *Breast J*. 2012;18:645-50. [doi:10.1111/bj.12016](https://doi.org/10.1111/bj.12016)
34. Ooe A, Takahara S, Sumiyoshi K, et al. Preoperative diagnosis of ductal carcinoma in situ arising within a mammary fibroadenoma: a case report. *J Clin Oncol*. 2011;41:918-23. [doi:10.1093/jco/hyr075](https://doi.org/10.1093/jco/hyr075)
35. Lin IL, Lee YH, Kao WS, et al. Pre-operative diagnosis of invasive ductal carcinoma within a fibroadenoma by mammography. *J Radiol Sci*. 2011;36:28-31. [doi:10.1097/pcr.0000000000000478](https://doi.org/10.1097/pcr.0000000000000478)
36. Kato F, Omatsu T, Matsumura W, et al. Dynamic MR findings of ductal carcinoma in situ within a fibroadenoma. *Magn Reson Med Sci*. 2011;10:129-32. [doi:10.2463/mrms.10.129](https://doi.org/10.2463/mrms.10.129)
37. Abu-Rahmeh Z, Nseir W, Naroditzky I, et al. Invasive ductal carcinoma within fibroadenoma and lung metastases. *Int J Gen Med*. 2012;5:19-21. [doi:10.2147/ijgm.s26115](https://doi.org/10.2147/ijgm.s26115)
38. Rao S, Latha PS, Ravi A, et al. Ductal carcinoma in a multiple fibroadenoma: diagnostic inaccuracies. *J Cancer Res Ther*. 2010;6:385-7. [doi:10.4103/0973-1482.73350](https://doi.org/10.4103/0973-1482.73350)
39. Petersson F, Tan PH, Putti CT, et al. Low-grade ductal carcinoma in situ and invasive mammary carcinoma with columnar cell morphology arising in a complex fibroadenoma in continuity with columnar cell change and flat epithelial atypia. *Int J Surg Pathol*. 2010;18:352-7. [doi:10.1177/1066896910373096](https://doi.org/10.1177/1066896910373096)
40. Tajima S, Kanemaki Y, Kurihara Y, et al. A case of a fibroadenoma coexisting with an invasive lobular carcinoma in the breast. *Breast Cancer*. 2011;18:319-23. [doi:10.1007/s12282-009-0122-z](https://doi.org/10.1007/s12282-009-0122-z)
41. Gashi-Luci LH, Limani RA, Kurshumliu FI, et al. Invasive ductal carcinoma within fibroadenoma: a case report. *Cases J*. 2009;2:1-4. [doi:10.1186/1757-1626-2-174](https://doi.org/10.1186/1757-1626-2-174)
42. Borecky N, Rickard M, et al. Preoperative diagnosis of carcinoma within fibroadenoma on screening mammograms. *J Med Imaging Radiat Oncol*. 2008;52:64-7. [doi:10.1111/j.1440-1673.2007.01913.x](https://doi.org/10.1111/j.1440-1673.2007.01913.x)
43. Tiu CM, Chou YH, Chiou SY, et al. Development of a carcinoma in situ in a fibroadenoma: color Doppler sonographic demonstration. *J Ultrasound Med*. 2006;25:1335-8. [doi:10.7863/jum.2006.25.10.1335](https://doi.org/10.7863/jum.2006.25.10.1335)
44. Shin JH, Choi HY, Lee SN, et al. Microinvasive ductal carcinoma arising within a fibroadenoma: a case report. *Acta Radiol*. 2006;47:643-5. [doi:10.1080/02841850600698838](https://doi.org/10.1080/02841850600698838)
45. Blanco M, Egozi L, Lubin D, et al. Adenoid cystic carcinoma arising in a fibroadenoma. *Ann Diagn Pathol*. 2005;9:157-9. [doi:10.1016/j.anndiagpath.2005.02.008](https://doi.org/10.1016/j.anndiagpath.2005.02.008)
46. Gogo-Abite M, Seleye-Fubara D, Jamabo RS, et al. Fibroadenoma coexisting with infiltrating ductal carcinoma: a case report. *Niger J Med*. 2005;14:221-3. [doi:10.4314/njm.v14i2.37185](https://doi.org/10.4314/njm.v14i2.37185)
47. Stafyla V, Kotsifopoulos N, GrigoriC ades K, et al. Lobular carcinoma in situ of the breast within a fibroadenoma: a case report. *Gynecol Oncol*. 2004;94:572-4. [doi:10.1016/j.ygyno.2004.04.031](https://doi.org/10.1016/j.ygyno.2004.04.031)
48. Abe H, Hanasawa K, Naitoh H, et al. Invasive ductal carcinoma within a fibroadenoma of the breast. *Int J Clin Oncol*. 2004;9:334-8. [doi:10.1007/s10147-004-0401-9](https://doi.org/10.1007/s10147-004-0401-9)
49. Adelekan MO, Tresadem JC, Prescott R, et al. Multiple metastatic deposits of a left breast cancer into a right fibroadenoma. *Breast*. 2003;12:294-6. [doi:10.1016/s0960-9776\(03\)00097-3](https://doi.org/10.1016/s0960-9776(03)00097-3)
50. Yano Y, Ueno E, Kamma H, et al. Non-invasive lobular carcinoma within a fibroadenoma: a preoperatively diagnosed case. *Breast Cancer*. 2001;8:70-3. [doi:10.1007/bf02967481](https://doi.org/10.1007/bf02967481)
51. Gebrim LH, Bernardes Júnior JR, Nazário AC, et al. Malignant phyllodes tumor in the right breast and invasive lobular carcinoma within fibroadenoma in the other: case report. *Sao Paulo Med J*. 2000;118:46-8. [doi:10.1590/s1516-3180200000200004](https://doi.org/10.1590/s1516-3180200000200004)
52. Psarianos T, Kench JG, Ung OA, et al. Breast carcinoma in a fibroadenoma: diagnosis by fine needle aspiration cytology. *Pathology*. 1998;30:419-21. [doi:10.1080/00313029800169736](https://doi.org/10.1080/00313029800169736)
53. Shah A, Pathak R, Banerjee S, et al. Lobular carcinoma-in-situ within a fibroadenoma of the breast. *Postgrad Med J*. 1999;75:293. [doi:10.1136/pgmj.75.883.293](https://doi.org/10.1136/pgmj.75.883.293)
54. Kurosumi M, Itokazu R, Mamiya Y, et al. Invasive ductal carcinoma with a predominant intraductal component arising in a fibroadenoma of the breast. *Pathol Int*. 1994;44:874-7. [doi:10.1111/j.1440-1827.1994.tb01687.x](https://doi.org/10.1111/j.1440-1827.1994.tb01687.x)
55. Morimoto T, Tanaka T, Komaki K, et al. The coexistence of lobular carcinoma in a fibroadenoma with a malignant phyllodes tumor in the opposite breast: report of a case. *Surg Today*. 1993; 23:656-60. [doi:10.1007/bf00311918](https://doi.org/10.1007/bf00311918)
56. Gupta RK, Dowle C, et al. Fine needle aspiration of breast carcinoma in a fibroadenoma. *Cytopathology*. 1992; 3:49-53. [doi:10.1111/j.1365-2303.1992.tb00022.x](https://doi.org/10.1111/j.1365-2303.1992.tb00022.x)
57. Gupta RK, Simpson J, et al. Carcinoma of the breast in a fibroadenoma: diagnosis by fine-needle aspiration cytology. *Diagn Cytopathol*. 1991; 7:60-2. [doi:10.1002/dc.2840070116](https://doi.org/10.1002/dc.2840070116)
58. Fukuda M, Nagao K, Nishimura R, et al. Carcinoma arising in fibroadenoma of the breast—A case report and review of the literature—. *Jpn J Surg*. 1989; 19:593-6. [doi:10.1007/bf02471669](https://doi.org/10.1007/bf02471669)
59. Yoshida Y, Takaoka M, Fukumoto M, et al. Carcinoma arising in fibroadenoma: case report and review of the world literature. *J Surg Oncol*. 1985; 29:132-40. [doi:10.1002/jso.2930290213](https://doi.org/10.1002/jso.2930290213)
60. Fondo EY, Rosen PP, Fracchia AA, et al. The problem of carcinoma developing in a fibroadenoma. *Cancer*. 1979; 43:563-7. [doi:10.1002/1097-0142\(197902\)43:2%3C563::AID-CNCR2820430224%3E3.0.CO;2-H](https://doi.org/10.1002/1097-0142(197902)43:2%3C563::AID-CNCR2820430224%3E3.0.CO;2-H)
61. Buzanowski-Konakry K, Harrison EG Jr, Payne WS, et al. Lobular carcinoma arising in fibroadenoma of the breast. *Cancer*. 1975; 35:450-6. [doi:10.1002/1097-0142\(197502\)35:2%3C450::AID-CNCR2820350223%3E3.0.CO;2-R](https://doi.org/10.1002/1097-0142(197502)35:2%3C450::AID-CNCR2820350223%3E3.0.CO;2-R)
62. Durso EA, et al. Carcinoma arising in a fibroadenoma: a case report. *Radiology*. 1972; 102:565. [doi:10.1148/102.3.565](https://doi.org/10.1148/102.3.565)