

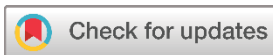Systematic Review

Recurrent Neurogenic Thoracic Outlet Syndrome (TOS): A Systematic Review of the Literature

Fahmi H. Kakamad^{1,2,3*}, Saywan K. Asaad^{1,2}, Abdullah K. Ghafour¹, Nsren S. Sabr¹, Soran H. Tahir^{1,2}, Belan M. Radha², Rezheen J. Rashid^{1,5}, Choman S. Omer¹, Rzgar H. Abdul⁴, Sanaa O. Karim^{1,6}, Berun A. Abdalla^{1,3}, Shvan H. Mohammed³, Suhaib H. Kakamad³

1. Smart Health Tower, Madam Mitterrand Street, Sulaimani, Kurdistan, Iraq
2. College of Medicine, University of Sulaimani, Madam Mitterrand Street, Sulaimani, Kurdistan, Iraq
3. Kscien Organization, Hamdi Street, Azadi Mall, Sulaimani, Kurdistan, Iraq
4. Shar Hospital, Sulaimani, Kurdistan, Iraq
5. Hiwa Hospital, Sulaimani, Kurdistan, Iraq
6. College of Nursing, University of Sulaimani, Madam Mitterrand Street, Sulaimani, Kurdistan, Iraq

* **Corresponding author:** fahmi.hussein@univsul.edu.iq (F.H. Kakamad). Doctor City, Building 11, Apartment 50, Zip code: 46001, Sulaimani, Iraq

**Keywords:**

Thoracic outlet syndrome
Recurrent nTOS
Nerve compression
Rib resection

Received: October 30, 2023
Revised: November 16, 2023
Accepted: November 28, 2023
Published: December 6, 2023

Copyright: © 2023 Kakamad et al. This is an open access article distributed under the terms of the Creative Commons Attribution License (<https://creativecommons.org/licenses/by/4.0/>), which permits unrestricted use, distribution, and reproduction in any medium, provided the original author and source are credited.

Citation: Kakamad FH, Asaad SK, Ghafour AK, Sabr NS, Tahir SH, Radha BM et al. Recurrent Neurogenic Thoracic Outlet Syndrome (TOS); a Systematic Review of the Literature. Barw Medical Journal. 2023 Dec 6;1(4):40-45.
<https://doi.org/10.58742/bmj.v1i2.45>

Abstract**Introduction**

Thoracic outlet syndrome (TOS) is a set of symptoms that arise when neurovascular bundles are compressed in the course of passage through three spaces: the costoclavicular junction, the scalene triangle, and the pectoralis minor space. This study aims to review the literature regarding the proper management of recurrent TOS.

Methods

We conducted a systematic literature search using various databases up to December 20, 2022. The study included those articles in which the symptoms were regarded as recurrent if TOS-related symptoms like pain and/or discomfort recurred following an initial resolution of symptoms. Multiple data were gathered from the included studies, including the publication year, first author, country, sex, age, type of primary intervention, duration of physiotherapy, type of reoperation, compressing structures, and the outcome.

Results

The study included 14 articles. Two of the articles were case reports, 10 were case series, and the remaining were cohort studies. A total of 686 patients were included, of whom 506 (73.7%) were female. The ages ranged from 17 to 79 years, with varying means across the age groups. Nine out of 14 (64%) studies reported the first rib remnant as one of the causative factors in the recurrence of TOS. Excellent or good results were reported in 474 (69%) patients.

Conclusion

Recurrent TOS is a relatively common finding after primary treatment for neurogenic TOS. Management is similar to primary TOS, including conservative management and surgical intervention. The latter should not be delayed if conservative treatment fails.

1. Introduction

Thoracic outlet syndrome (TOS) is a set of symptoms that arise when neurovascular bundles are compressed in the course of

passage through three spaces: the costoclavicular junction, the scalene triangle, and the pectoralis minor space [1,2]. According to the structure being compressed, TOS is classified into three

main categories; neurogenic (nTOS), arterial (aTOS), and venous (vTOS) [1]. nTOS is more prevalent among women and is most often seen in otherwise healthy, moderately active, and relatively young adults [3]. Frequently, nTOS is demonstrated by pain in the neck and upper extremities, numbness, paresthesia, and weakness, with positional exacerbation of the symptoms [4]. However, there is controversy about the overall knowledge of nTOS, like pathogenesis, diagnosis, treatment, and prognosis. Favorable outcomes have been obtained among a large group of properly selected patients who undergo thoracic outlet decompression, as indicated by multiple studies [4-6]. Even the vast majority of affected patients with nTOS, including those who sustained work-related injuries and sought compensation, reported post-surgery symptom improvement and expressed willingness to undergo decompression surgery again when necessary [7]. Decompression may include first rib and/or cervical rib resection, anterior and middle scalene muscle division or resection, anomalous fibro-facial band resection, and/or brachial plexus mobilization with perineural fibrous tissue (external neurolysis) resection [4].

Following the first rib resection or scalenectomy, recurrent symptoms of TOS are possible. Regardless of the type of surgical procedure that has been carried out, a recurrence rate of 15%–30% has been reported [8]. This study aims to review the literature regarding the proper management of recurrent TOS.

2. Methods

2.1. Study protocol

This review was designed based on the Preferred Reporting Items for Systematic Reviews and Meta-Analyses (PRISMA) 2020 guidelines [9].

2.2. Data sources and search strategy

A systematic literature search was conducted using Google Scholar, PubMed/MEDLINE, Web of Science, CINAHL, Cochrane Library, and EMBASE databases to identify published studies up to December 20, 2022. The search was performed using these keywords: (recurrence OR recurrent OR reoperation) AND (TOS OR Thoracic outlet syndrome). The search was focused on English language studies.

2.3. Eligibility criteria

The study included those articles in which the symptoms were regarded as recurrent if TOS-related symptoms of pain and/or discomfort recurred following an initial resolution of symptoms. Studies with minimal improvement or persistent symptoms and only abstracts available were excluded. All cited resources were assessed for eligibility according to Kscien's criteria [10].

2.4. Study selection process

At first, two independent researchers (BAA and SOK) screened the titles and abstracts of the searched studies and later performed a full-text screening based on the eligibility criteria. Then, the eligible studies were selected. The third author (FHK)

resolved any disagreement through discussion and debate with the former ones.

2.5. Data items

Multiple data were gathered from the included studies, including the publication year, first author, country, sex, age, type of primary intervention, duration of physiotherapy, type of reoperation, compressing structures, and the outcome.

2.6. Data analysis and synthesis

The extracted data were analyzed qualitatively using the Statistical Package for Social Sciences (SPSS) 25.0 software. A summary table containing relevant variables was produced and presented as frequency, mean, range, and percentage.

3. Results

After removing the excluded articles according to the eligibility criteria (Figure 1), the study included 14 articles [1,3,4-6,7,11-18]. Two of the articles were case reports, 10 were case series and the remaining were cohort studies. The study included 686 patients, and 506 (73.7%) were female. The ages ranged from 17 to 79 years, with varying means across the age groups. Nine out of 14 (64%) studies reported the first rib remnant as one of the causative factors in the recurrence of TOS. Excellent or good results were reported in 474 (69%) patients. Table 1 and 2 show the details of each study.

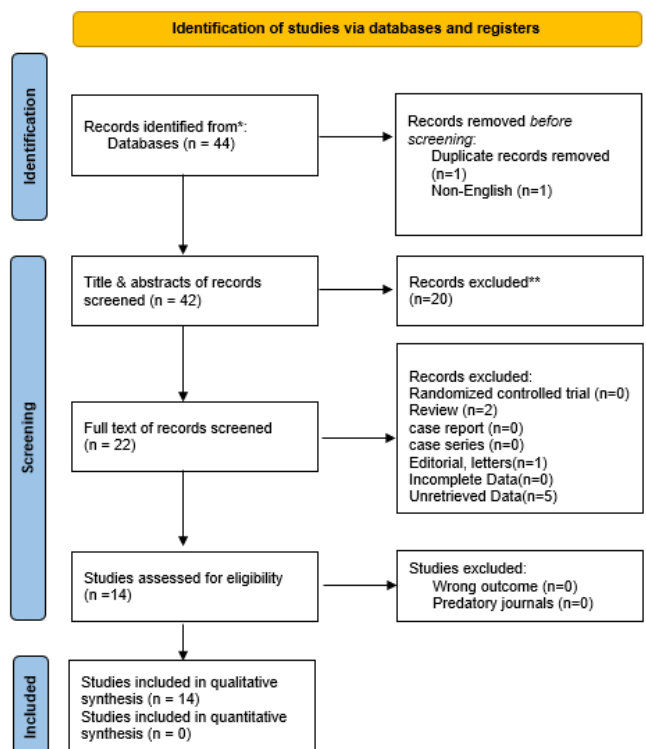


Figure 1. Study selection PRISMA flow chart.

Table 1. Full description of the cases and corresponding recommendations.

Author/Reference	Country/Year	Study design	No. of patients	Age/ age range	Gender
Gadiwalla et al. [1]	USA/2022	Case Report	1	30	F
Wiley et al. [15]	USA/2022	Case Report	1	40	F
Jammeh et al. [3]	USA/2021	Cohort Study	90	39.9*	25M/65F
Greenberg et al. [18]	USA/2015	Case series	20	34.8*	8M/12F
Likes et al. [2]	USA/2014	Case Series	15	36.5*	4M/11F
Gelabert et al. [9]	USA/2014	Case Series	8	40.8*	2M/6F
Sanders [10]	USA/2011	Cohort study	86	17-71	17M/69F
Chalela et al. [4]	USA/2004	Case series	17	23-50	2M/15F
Stephen et al. [6]	USA/1994	Case series	38	40*	5M/33F
Sanders et al. [11]	USA/1990	Case Series	97	32*	20M/77F
Urschel et al. [12]	USA/1986	Case series	225	23-68	79M/146F
Sessions [13]	USA/1982	Case series	29	NR	6M/23F
Sanders et al. [16]	USA/1979	Case Series	29	20-51	3M/26F
Urschel et al. [14]	USA/1976	Case series	30	21-70	9M/21F

4. Discussion

Regardless of the initial operative approach, recurrence or persistent symptoms of nTOS have been reported in 15% to 30% of patients, in spite of the magnificent outcome of surgical treatment [4,8]. Although it is rare, concurrent TOS with nTOS can occur after inadequate first and/or cervical rib excision [1]. Recurrence differs from immediate failure. The former is considered when the patient initially experiences symptomatic improvement for a period, then develops symptoms and can benefit from reoperation. While the latter includes patients with no symptomatic improvement after the initial surgery, either from diagnosis error or dominating another diagnosis, they can take no benefit from reoperation [12].

It is common for the residual first rib to be the cause of symptom recurrence. However, the incidence of first rib regrowth is unknown. As the literature reported, the fewest number of patients after the initial operation were noted to have the first rib regrow [12,18].

Bone regrowth needs the presence of fibroblasts and precursor cells, presumably from the periosteum. These precursor cells develop to form chondroblasts and osteoblasts. Bone growth is preceded by hyaline cartilage production from chondroblasts, which is the probable explanation for fibrocartilaginous extensions to the regrown bone, as seen in several specimens. In addition, residual elements of incompletely resected original ribs have been noted. It is worthwhile to note that first rib regrowth is probably correlated with residual rib portions, including non-resected periosteum and bone [12].

Diagnostic testing is advised for two reasons: to rule out the differential diagnosis and to assist in the diagnosis of TOS [19].

Additionally, recurrent TOS is rather easier to diagnose than establishing the diagnosis with initial symptoms. A short period of symptom relief could be considered evidence that the TOS diagnosis was probably correct [12].

Differential diagnosis exclusion is carried out through physical examination, electroconductive testing, and evaluation of cervical spine magnetic resonance imaging (MRI). These assessments are carried out for all patients at the time of the initial surgery. As recurrent symptoms have been recognized, repeating these tests is considered. A number of tests are considered to assist and support the diagnosis of recurrent TOS, including anterior scalene muscle block, electroconductive testing, and brachial plexus MRI studies [19,20]. Venography of the upper extremities is carried out whenever congestive symptoms are present [11].

Moreover, the presence of other differential diagnoses makes TOS diagnosis difficult but does not exclude it, as the majority of the patients have more than one diagnosis. Sometimes, when no neurologic improvement is observed after TOS surgery, brachial plexus injury, which is a diagnosis of exclusion, can be considered after ruling out entrapment in all other areas (spine, wrist, elbow) [5,11].

Recurrent TOS is categorized, based on the location of brachial plexus fixation, into lower tract recurrence (Roos type 1) and upper tract recurrence (Roos type 2). The former, Roos type 1, roots of C8-T1 are fixed to the chest wall by the scar of the retained first rib stump, while the latter nerve roots of one or all of the C5, C6, or C7 are attached almost through anterior scalene muscle re-attachment, which is tied down to the neck. Additionally, complete recurrence is also described, and its

Table 1. Summary of the reviewed studies of recurrent thoracic outlet syndrome.

Author/reference	Primary intervention	Duration of physiotherapy	Type of re-operation	Compressing structures	Outcome
Gadiwalla et al. [1]	Open thromboembolotomy, 1st rib resection, partial excision of cervical rib, and graft interposition	NR	Right-sided first rib and cervical rib resection by supraclavicular and infraclavicular approach	First rib remnant	Improved
Wiley et al. [15]	Infraclavicular left first rib resection	NR	Transaxillary first rib residual and anterior scalene muscle removal	Residual 1st rib and 2nd rib	Improved
Jammeh et al. [3]	Supraclavicular/transaxillary/multiple combinations decompression of residual scalene muscle and residual first rib	6 weeks	Supraclavicular decompression	Anterior and middle scalene muscle remnant/fibro-facial band/scar tissue/cervical and first rib remnant	10% excellent/ 36% good/ 43 %fair / 11% poor
Greenberg et al. [18]	Transaxillary first rib resection/ supraclavicular resection	3-6 months	transaxillary rib resection / supraclavicular re-exploration	Scar tissue/ regrowth/ incomplete previous resections	80% improved
Likes et al. [2]	Supraclavicular first rib resection and scalenectomy /transaxillary first rib resection	NR	Supraclavicular first rib resection and scalenectomy / transaxillary first rib resection/ residual scalene resection/ lysis of scar tissue	Residual first rib/anterior scalene muscle remnant/scar tissue	All improved
Gelabert et al. [9]	Supraclavicular first rib resection/ transaxillary first rib resection/ scalenectomy/ cervical rib resection	NR	Transaxillary resection of the regrown first rib/ neurolysis of the brachial plexus/ scalenectomy, and lysis of subclavian vein	Regrown 1st rib	50% improved
Sanders [10]	Supraclavicular scalenectomy/ transaxillary first rib resection	NR	Pectoralis minor tenotomy alone or in combination with brachial plexus decompression	NR	69% good, 8% fair, 23% failure / 58% good, 20% fair, 22% failure
Chalela et al. [4]	Surgical decompression of osseous or musculotendinous structures	8 weeks	Removal of intact or residual rib/ pectoralis minor tenotomy/ brachial plexus neurolysis/ or a combination of them.	Residual first rib/adherent residual scalene muscle /ectopic band/compression by intact 1st rib and 2nd rib or pectoralis minor tendon	All improved
Stephen et al. [6]	Scalenotomy/ scalenectomy/ Scalenectomy and cervical rib excision/ Scalenectomy and first rib excision/ Scalenectomy and first and cervical rib excision/ first rib excision/ neurolysis by supraclavicular/ transaxillary/ combined supraclavicular and transaxillary/ Parascapular infraclavicular	NR	complete decompression of the thoracic outlet by scalenectomy followed by a thorough neurolysis through supraclavicular approach	residual cervical ribs or long posterior stumps of the first rib	75% improved

Table 2. Continued...

Gadiwalla et al. [1]	Open thromboembolotomy, 1st rib resection, partial excision of cervical rib, and graft interposition	NR	Right-sided first rib and cervical rib resection by supraclavicular and infraclavicular approach	First rib remnant	Improved
Wiley et al. [15]	Infraclavicular left first rib resection	NR	Transaxillary first rib residual and anterior scalene muscle removal	Residual 1st rib and 2nd rib	Improved
Jammeh et al. [3]	Supraclavicular/transaxillary/multiple combinations decompression of residual scalene muscle and residual first rib	6 weeks	Supraclavicular decompression	Anterior and middle scalene muscle remnant/fibro-facial band/scar tissue/cervical and first rib remnant	10% excellent/ 36% good/ 43 %fair / 11% poor
Greenberg et al. [18]	Transaxillary first rib resection/ supraclavicular resection	3-6 months	transaxillary rib resection / supraclavicular re-exploration	Scar tissue/ regrowth/ incomplete previous resections	80% improved
Likes et al. [2]	Supraclavicular first rib resection and scalenectomy/transaxillary first rib resection	NR	Supraclavicular first rib resection and scalenectomy / transaxillary first rib resection/ residual scalene resection/ lysis of scar tissue	Residual first rib/anterior scalene muscle remnant/scar tissue	All improved

diagnosis and treatment are challenging as the brachial plexus scar is fixed to both the chest wall and the neck [13].

Some literature considers incomplete rib excision during the initial operation of TOS as the principal iatrogenic cause of recurrence. Besides, it is also stated that the brachial plexus can be compressed by fibrous cartilage and bone formed after incomplete rib resection. As reported, the majority (87%) of TOS recurrence comes with the posterior stump of the first rib, and the least number of patients show non-improvement after the second operation [3]. Furthermore, scar tissue in the bed of the first rib or compression between the second rib and clavicle have been suggested as causative factors. Herein, it is recommended to carry out axillary re-exploration for scar tissue division in the bed of the first rib and second rib midpoint removal when costoclavicular compression is noted [14].

Many surgeons are reportedly dissatisfied with anterior scalenotomy due to its high failure rates [21]. However, different studies revealed different outcomes, since some of the studies reported similar outcomes in describing success rates of first rib resection alone and scalenectomy alone when anterior scalenotomy was substituted by anterior and middle scalenectomy. Further studies support scalenectomy with better outcomes and fewer complications compared to transaxillary first rib resection [11,22-25].

Similar to primary TOS, management of recurrent TOS should start with conservative treatment, including physiotherapy, injections in the trigger point, job modifications, and medications (analgesic soothing cream, liniments, and muscle relaxants). When surgical treatment is required as the last resort, depending on the previous procedures that have been carried out, the type of surgical approach is chosen [25].

The surgical outcome of recurrent TOS is very similar to the outcome of primary TOS, with 84% of patients showing initial improvement, falling to 59% after 1-2 years and 41% at 10-15 years [11].

Two years after the initial operation, recurrence is possible but less common. The cause of recurrence significantly influences the outcome of reoperation. Additionally, continuous scarring at the site of the previous operation is considered to be the cause of spontaneous recurrence, resulting in a less favorable outcome of reoperation [11].

5. Conclusion

Recurrent TOS is a relatively common finding following primary treatment for neurogenic TOS. Management is similar to primary TOS, including conservative management and surgical intervention. The latter should not be delayed if conservative treatment fails.

Declarations

Conflicts of interest: The author(s) have no conflicts of interest to disclose.

Ethical approval: Not applicable, as meta-analyses do not require ethical approval.

Patient consent (participation and publication): Not applicable.

Funding: The present study received no financial support.

Acknowledgements: None to be declared.

Authors' contributions: BAA, BMM and SOK participated in data collection; FHK designed the study; SHM performed the data analysis; RJR and CSO participated in preparing the manuscript; SKA, AKG, RHA, SHK and NSS critically revised the manuscript; FHK and SHT confirmed the authenticity of the data; all authors approved the final version of the manuscript.

Data availability statement: Note applicable.

References

- Gadiwalla Q, Dong S, Recarey M, Nguyen B, Lala S. Recurrent arterial and new-onset neurogenic thoracic outlet syndrome as a complication after previously inadequately excised first and cervical ribs. *Journal of Vascular Surgery Cases, Innovations and Techniques*. 2022 ;8(3):328-30. [doi:10.1016/j.jvscit.2022.04.011](https://doi.org/10.1016/j.jvscit.2022.04.011)
- Joseph L.Lukad. Controversies in Thoracic Outlet Syndrome. *Barw Medical Journal*. 2023;1(3):1. [doi:10.58742/BMJ.V1I2.40](https://doi.org/10.58742/BMJ.V1I2.40)
- Likes K, Dapash T, Rochlin DH, Freischlag JA. Remaining or residual first ribs are the cause of recurrent thoracic outlet syndrome. *Annals of Vascular Surgery*. 2014; 28(4):939-45. [doi:10.1016/j.avsg.2013.12.010](https://doi.org/10.1016/j.avsg.2013.12.010)
- Jammeh ML, Ohman JW, Vemuri C, Abuirqeba AA, Thompson RW. Anatomically complete supraclavicular reoperation for recurrent neurogenic thoracic outlet syndrome: clinical characteristics, operative findings, and long-term outcomes. *Hand*. 2022; 17(6):1055-64. [doi:10.1177/1558944720988079](https://doi.org/10.1177/1558944720988079)
- Sanders RJ. Recurrent neurogenic thoracic outlet syndrome stressing the importance of pectoralis minor syndrome. *Vascular and endovascular surgery*. 2011;45(1):33-8. [doi:10.1177/1538574410388311](https://doi.org/10.1177/1538574410388311)
- Cheng SW, Stoney RJ. Supraclavicular reoperation for neurogenic thoracic outlet syndrome. *Journal of vascular surgery*. 1994;19(4):565-72. [doi:10.1016/S0741-5214\(94\)70027-3](https://doi.org/10.1016/S0741-5214(94)70027-3)
- Ambrad-Chalela E, Thomas GI, Johansen KH. Recurrent neurogenic thoracic outlet syndrome. *The American journal of surgery*. 2004; 187(4):505-10. [doi:10.1016/j.amjsurg.2003.12.050](https://doi.org/10.1016/j.amjsurg.2003.12.050)
- Annest SJ, Melendez BA, Sanders RJ. Recurrent and residual neurogenic thoracic outlet syndrome. *Thoracic Outlet Syndrome*. 2021:333-40. [doi:10.1007/978-3-030-55073-8_34](https://doi.org/10.1007/978-3-030-55073-8_34)
- Page MJ, McKenzie JE, Bossuyt PM, Boutron I, Hoffmann TC, Mulrow CD, Shamseer L, Tetzlaff JM, Akl EA, Brennan SE, Chou R. The PRISMA 2020 statement: an updated guideline for reporting systematic reviews. *International journal of surgery*. 2021; 88: 105906. [doi:10.1016/j.ijssu.2021.105906](https://doi.org/10.1016/j.ijssu.2021.105906)
- Muhaldeen AS, Ahmed JO, Baba HO, Abdullah IY, Hassan HA, Najjar KA, et al. Kscien's List; A New Strategy to Discourage Predatory Journals and Publishers (Second Version). *Barw Medical Journal*. 2023. [doi:10.58742/BMJ.V1I1.14](https://doi.org/10.58742/BMJ.V1I1.14)
- Sanders RJ, Haug CE, Pearce WH. Recurrent thoracic outlet syndrome. *Journal of vascular surgery*. 1990;12(4):390-400. [doi:10.1016/0741-5214\(90\)90040-H](https://doi.org/10.1016/0741-5214(90)90040-H)
- Gelabert HA, Jabori S, Barleben A, Kiang S, O'Connell J, Jimenez JC, DeRubertis B, Rigberg D. Regrown first rib in patients with recurrent thoracic outlet syndrome. *Annals of Vascular Surgery*. 2014;28(4):933-8. [doi:10.1016/j.avsg.2014.01.004](https://doi.org/10.1016/j.avsg.2014.01.004)
- Sessions RT. Recurrent thoracic outlet syndrome: causes and treatment. *Southern Medical Journal*. 1982;75(12):1453-61. [doi:10.1097/00007611-198212000-00004](https://doi.org/10.1097/00007611-198212000-00004)
- Sanders RJ, Monsour JW, Gerber WF. Recurrent thoracic outlet syndrome following first rib resection. *Vascular Surgery*. 1979;13(5):325-30. [doi:10.1177/153857447901300505](https://doi.org/10.1177/153857447901300505)
- Urschel Jr HC, Razzuk MA. The failed operation for thoracic outlet syndrome: the difficulty of diagnosis and management. *The Annals of thoracic surgery*. 1986;42(5):523-8. [doi:10.1016/S0003-4975\(10\)60574-7](https://doi.org/10.1016/S0003-4975(10)60574-7)
- Urschel Jr HC, Razzuk MA, Albers JE, Wood RE, Paulson DL. Reoperation for recurrent thoracic outlet syndrome. *The Annals of Thoracic Surgery*. 1976;21(1):19-25. [doi:10.1016/S0003-4975\(10\)64882-5](https://doi.org/10.1016/S0003-4975(10)64882-5)
- Wiley AP, Costa CG, Pothering CA, Freischlag JA. Residual first rib resection aided by partial second rib resection in the treatment of recurrent thoracic outlet syndrome. *Annals of Vascular Surgery-Brief Reports and Innovations*. 2022;2(3):100118. [doi:10.1016/j.avsg.2022.100118](https://doi.org/10.1016/j.avsg.2022.100118)
- Greenberg JI, Alix K, Nehler MR, Johnston RJ, Brantigan CO. Computed tomography-guided reoperation for neurogenic thoracic outlet syndrome. *Journal of Vascular Surgery*. 2015;61(2):469-74. [doi:10.1016/j.jvs.2014.07.008](https://doi.org/10.1016/j.jvs.2014.07.008)
- Povlsen S, Povlsen B. Diagnosing thoracic outlet syndrome: current approaches and future directions. *Diagnostics*. 2018;8(1):21. [doi:10.3390/diagnostics8010021](https://doi.org/10.3390/diagnostics8010021)
- Braun RM, Shah KN, Rechnic M, Doehr S, Woods N. Quantitative assessment of scalene muscle block for the diagnosis of suspected thoracic outlet syndrome. *The Journal of Hand Surgery*. 2015;40(11):2255-61. [doi:10.1016/j.jhsa.2015.08.015](https://doi.org/10.1016/j.jhsa.2015.08.015)
- Martinez BD, Wiegand CS, Evans P, Gerhardinger A, Mendez J. Computer-assisted instrumentation during endoscopic transaxillary first rib resection for thoracic outlet syndrome: a safe alternate approach. *Vascular*. 2005;13(6):327-35. [doi:10.1258/rsmvasc.13.6.327](https://doi.org/10.1258/rsmvasc.13.6.327)
- Suzuki T, Kimura H, Matsumura N, Iwamoto T. Surgical approaches for thoracic outlet syndrome: a review of the literature. *Journal of Hand Surgery Global Online*. 2022;73(6):2059-63. [doi:10.1016/j.jhsg.2022.04.007](https://doi.org/10.1016/j.jhsg.2022.04.007)
- Rochlin DH, Orlando MS, Likes KC, Jacobs C, Freischlag JA. Bilateral first rib resection and scalenectomy is effective for treatment of thoracic outlet syndrome. *Journal of vascular surgery*. 2014;60(1):185-90. [doi:10.1016/j.jvs.2014.01.034](https://doi.org/10.1016/j.jvs.2014.01.034)
- Johansen K. Rib-Sparing scalenectomy for neurogenic thoracic outlet syndrome: Early results. *Journal of Vascular Surgery*. 2021;73(6):2059-63. [doi:10.1016/j.jvs.2020.12.052](https://doi.org/10.1016/j.jvs.2020.12.052)
- Atasoy E. Recurrent thoracic outlet syndrome. *Hand Clinics*. 2004;20(1):99-105. [doi:10.1016/S0749-0712\(03\)00085-4](https://doi.org/10.1016/S0749-0712(03)00085-4)