

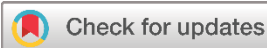Case Report

Desmoplastic Small Round Cell Tumor: A Case Report

Rebaz Haji Ali^{1,2}, Shano M. Ali², Rawa M. Ali¹, Soran H. Tahir^{1,3}, Shad Nasir Mohammed^{3*}, Dana T. Gharib^{1,4}, Zana Baqi Najmadden⁵, Hoshmand R. Asaad^{1,4}, Deari A. Ismaeil^{1,3}, Omar H. Ghalib Hawramy¹

1. Smart Health Tower, Scientific Affairs Department, Madam Mitterrand Street, Sulaimani, Kurdistan, Iraq
2. Hiwa Cancer Hospital Centre, Sulaimani Directorate of Health, Sulaimani, Kurdistan, Iraq
3. College of Medicine, University of Sulaimani, Sulaimani, Kurdistan, Iraq
4. Gastroenterology and Hepatology Teaching Hospital, Sulaimani, Kurdistan Region, Iraq
5. Research Center, University of Halabja, Halabja, Kurdistan Region, Iraq

* **Corresponding author:** Shad.nasrxayat2002@gmail.com (S.N. Mohammed). Hawari Shar Street, House number 155/158, Zip code: 46001, Sulaimani, Iraq

**Keywords:**

DSRCT
VAC-IE chemotherapy
Rare abdominal metastasis

Received: November 10, 2023
Revised: November 25, 2023
Accepted: December 17, 2023
Published: December 28, 2023

Copyright: © 2023 Ali et al. This is an open access article distributed under the terms of the Creative Commons Attribution License (<https://creativecommons.org/licenses/by/4.0/>), which permits unrestricted use, distribution, and reproduction in any medium, provided the original author and source are credited.

Citation: Ali RH, Ali SM, Ali RM, Tahir SH, Mohammed SN, Gharib DT, et al. Desmoplastic Small Round Cell Tumor: A Case Report. Barw Medical Journal. 2023 Dec 28;1(4):51-55.
<https://doi.org/10.58742/etbs9n84>

Abstract**Introduction**

Desmoplastic small round cell tumor (DSRCT) is an ultra-rare and highly aggressive mesenchymal tumor that primarily affects the peritoneum, and to a lesser extent, the visceral organs in the abdominal cavity. This study presents a case of a patient who has been diagnosed with DSRCT and has been managed with VAC-IE chemotherapy.

Case presentation

A 43-year-old male presented with a complaint of epigastric pain for 20 days but no other clinical symptoms. A CT scan and an abdominal ultrasound showed multiple lesions in the peritoneum, and biopsies were taken from all the sites. Histological analysis revealed nests of small blue round cells surrounded by an abundant stroma. Immunohistochemistry results confirmed the disease to be a desmoplastic small round cell tumor.

Conclusion

This disease is yet to be fully understood, and the response of our case to VAC-IE chemotherapy has shown promising outcomes. This form of treatment can be further studied to establish and help in finding a treatment with a better prognosis.

1. Introduction

Desmoplastic Small Round Cell Tumor (DSRCT) is an exceedingly rare and aggressive form of soft tissue sarcoma, showing a higher incidence among males, with an estimated male-to-female ratio ranging from 5:1 to 10:1. [1-3]. The tumor has an incidence rate of 0.0002% to 0.0005%, with a total of about 200 to 500 reported cases. It is more frequently observed among individuals aged 20 to 30, with a median age of onset of 19 years [2,4,5]. DSRCT primarily manifests within the

abdominal region, particularly in the retroperitoneum, pelvis, peritoneum, or mesentery. In rare instances, it can also affect the kidneys and ovaries. At the time of presentation, nearly all patients exhibit peritoneal metastases, while approximately half of them may present with extra-peritoneal metastases [4,5].

Specific clinical manifestations are generally absent in DSRCT, with common symptoms typically revolving around abdominal or pelvic pain. The absence of distinct symptoms complicates diagnosis, often resulting in advanced metastasis at the time of

identification. The main features of DSRCT include a predilection for adolescent males, a primary intraabdominal location typically affecting serosal surfaces, a nesting growth pattern, focal rhabdoid morphology, a notable desmoplastic reaction, immunohistochemical reactivity for epithelial, neural, and muscle markers, and a highly aggressive clinical course [6]. The 5-year overall survival (OS) rate is a mere 15% to 25%, and the median survival time is approximately 2 years. [7]. Long-term survival has been reported in just 8% of patients with metastatic or locally advanced unresectable soft tissue sarcoma [8]. Although DSRCT is susceptible to chemotherapy, it frequently experiences recurrence [3]. Due to similarities with other malignancies and its occurrence in visceral organs such as kidneys or the liver, differentiating DSRCT through radiological and pathological means poses a significant challenge [2].

Herein, we aim to report a case of DSRCT and discuss the clinical course of its diagnosis and treatment.

2. Case Presentation

2.1. Patient information

A 43-year-old male presented to Hiwa Cancer Hospital, Sulaymaniyah, Iraq, in September 2022 with epigastric pain lasting for 20 days, exacerbated by eating, without vomiting, diarrhea, fever, or jaundice. He had a negative medical and surgical history, no chronic drug use, and no drug allergies.

2.2. Clinical findings

Physical examination revealed epigastric tenderness, normal vital signs, no palpable mass, and no signs of jaundice.

2.3. Diagnostic assessment

Blood investigations revealed normal complete blood count, alkaline phosphatase (143 IU/L, normal range; 44-147 IU/L), alanine transaminase (39 IU/L, normal range; <50 IU/L), aspartate aminotransferase (30 IU/L, normal range; 8-33 IU/L), total serum bilirubin (0.44 mg/dL, normal range; 0.3–1.2mg/dL), blood urea (22.2 mg/dL, normal range; 16-45 mg/dL), and serum creatinine (0.8 mg/dL, normal range; 0.7-1.2 mg/dL).

A total colonoscopy with a terminal ileal examination was performed, revealing normal mucosa and vascular pattern with no masses, polyps, or ulcers detected, except for an anal fissure.

Abdominal ultrasound showed a large epigastric mass (91 x 45 mm), slightly to the right (in the region of the head of the pancreas). The mass exhibited a heterogeneous texture and internal vascularity and was surrounded by free fluid. Adjacent to it, an echogenic mass lesion (85 x 30 mm) was also observed. In the left lobe of the liver, at least 2 lesions were present, with the larger one measuring 22 x 14 mm.

A computed tomography (CT) scan of the abdomen and pelvis was performed, revealing multiple enhancing soft tissue nodules of variable size and shape distributed diffusely throughout the

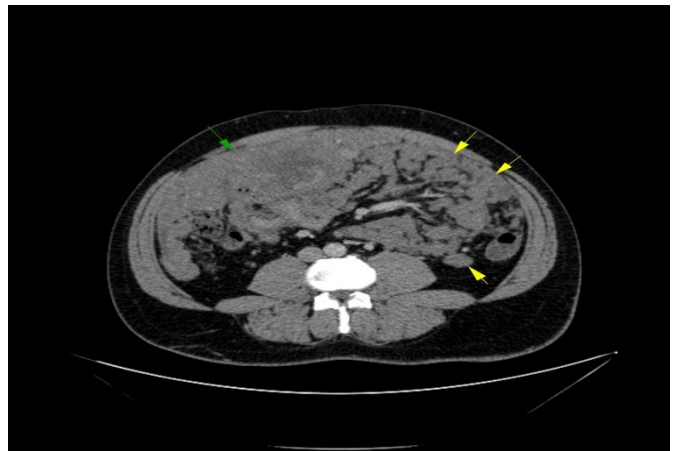

Figure 1. CT abdomen with IV contrast, shows large mass in right side of abdomen in between abdominal wall and bowel loops "green arrow", multiple conglomerate peritoneal nodules "yellow arrows"

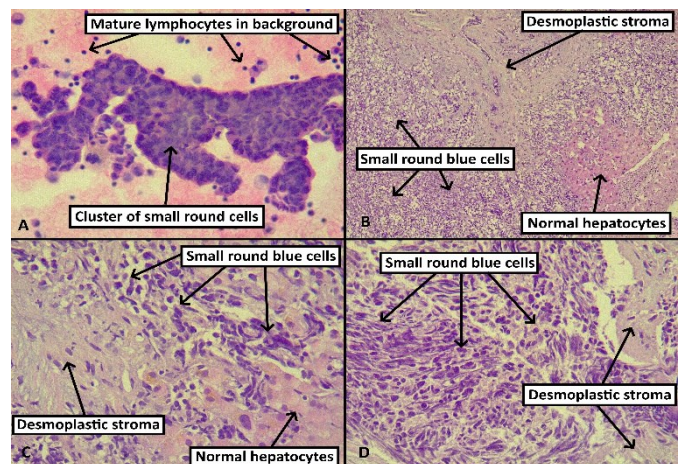


Figure 2. A) Smear from fine needle aspiration shows tight clusters of cells with large, hyperchromatic nuclei that have irregular nuclear outlines and scant lightly eosinophilic cytoplasm, admixed with mature mononuclear inflammatory cells. B-C) Sheets of small round blue cells are admixed with desmoplastic stroma within the hepatic parenchyma. D) The tumor cells have large, hyperchromatic nuclei with irregular nuclear outlines and scant lightly eosinophilic cytoplasm. Desmoplastic stroma surrounds the tumor cells. [Hematoxylin and eosin, 400x (A, C, and D) and 40x (B) magnification.

peritoneal cavity. Nodules were also found in the right and left paracolic gutters, extending under the spleen and liver into the pelvis. A conglomerated mass on the right side of the mid-abdomen was found just under the anterior abdominal wall, measuring 7.5 x 10 x 13 cm, and a 34 x 54 x 41 mm mass was observed in the retrovesical region. The latter one was in contact with the anterior rectum and associated with multiple hepatic lesions. Mild ascites in the right and left paracolic gutters also

revealed diffuse, multiple hypoattenuated hypovascular lesions. The largest lesion measured around 2 cm in the omental region (figure 1). Liver and peritoneal lesion biopsies were performed, all showing DSRCT (figure 2). The specimen obtained through biopsy was placed into tissue cassettes.

Subsequently, the tissue cassettes underwent a standardized 11-hour processing procedure with the use of alcohol, xylene, and paraffin in the DiaPath Donatello automated processor. After paraffin embedding and trimming, the blocks were sliced into sections measuring 4 to 6 micrometers, which were then placed on regular glass slides. These slides were incubated in an oven set at 60°C overnight and subsequently subjected to staining using the DiaPath Giotto automated stainer with a 1% solution for 10 minutes, specifically for hematoxylin and eosin (H&E)

staining, utilizing Gill II hematoxylin. Following the staining process, the slides were dried, and coverslips were affixed. The examination of the slides was conducted using a light microscope (Leica Microsystems, Germany). Immunohistochemistry results were as follows: AE1/AE3 (Bio SB, clone AE1/AE3, LOT number 5433QIG05, pH 6, dilution 1:2) exhibited strong diffuse staining for both round cells and stromal cells; desmin (Dako, clone D33, LOT number 20034392, pH 9, dilution 1:1.3) was positive for round cells, while synaptophysin (Dako, clone DAK-SYNAP, LOT number 20040445, pH 9, dilution 1:2) and TTF1 (Dako, clone 8G7G3/1, LOT number 10118965, pH 6, dilution 1:0.5) were negative (figure 3).

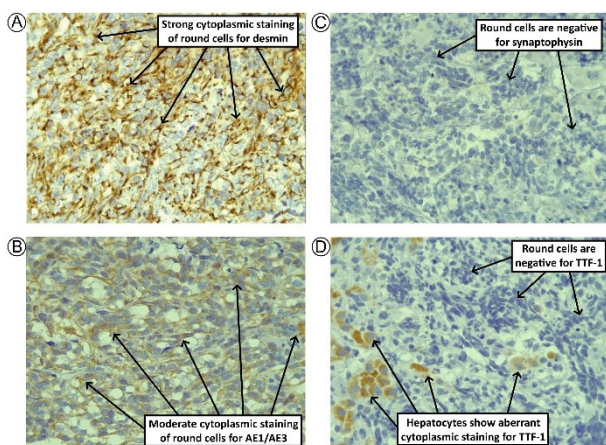


Figure 3. A) The small round blue cells show cytoplasmic staining of strong intensity with antibodies to desmin. B) The small round blue cells show cytoplasmic staining of moderate intensity with the cytokeratin cocktail AE1/AE3. C) The small round blue cells stain negative with synaptophysin. D) The small round blue cells stain negative with TTF-1. Normal hepatocytes show aberrant cytoplasmic staining. [Immunohistochemistry using diaminobenzidine chromogen; 400x magnification].

The slides were incubated up to a maximum temperature of 100 degrees Celsius for a total incubation time of 2 hours with the purpose of antigen retrieval on the initial tissue sections. The slides were boiled using the Dako PT Link in a solution with a pH of either 6 or 9 (depending on the requirement of the target

antibody). The device preheated the slides from 30 degrees centigrade upwards to a boiling temperature of 100 degrees centigrade for 45 minutes, followed by cooling down to 65 degrees centigrade for a total operation time of 2 hours. Later on, during the step of application of the primary antibody, the slides were covered with 50 microns of the primary antibody diluted according to each antibody's manufacturer's recommendations, and kept for 45 minutes. There is no heating or incubation during this step.

We did not use a quantitative or objective scale. The intensity was generally assessed in a relatively subjective manner based on how "bright" and "easily visible" the staining was from low magnification. If the staining was bright, strong, and distinct from low magnification (often compared to how strong the external control was), it was designated "strong". If it was weak, faint, and visible mainly from high magnification, it was designated "weak". If it was somewhere in between, it was designated "moderate". All of the tissues used as external controls were taken from other cases of human specimens that were already signed out. This included cases of appendicitis or those with reactive lymphoid hyperplasia. Similarly, thyroid tissues from cases of follicular nodular disease were used. We used standard, relevant external controls for all stains. The vermiform appendix was used for desmin, AE1/AE3, and synaptophysin. Thyroid tissue was used for TTF-1. The internal control for AE1/AE3 was the hepatocytes and bile ducts. TTF-1 showed aberrant cytoplasmic staining in hepatocytes. Desmin only stained the smooth muscle in the walls of larger vessels. Synaptophysin had no internal control in this case.

2.3. Therapeutic intervention

The patient received chemotherapy in the form of VAC-IE, which included doxorubicin 1.136 g/8 cycles, Mesna 10.944 g/16 cycles, vincristine 32 mg/16 cycles, cyclophosphamide 36.48 g/16 cycles, etoposide 3.04 g/16 cycles, and ifosfamide 54.72 g/16 cycles. The treatment was administered every 21 days for 16 cycles. Due to its high toxicity, doxorubicin was used for only 8 cycles.

2.4. Follow-up

After eight months, CT scans of the chest, abdomen, and pelvis were conducted. The results indicated the resolution of some hepatic lesions, no detection of new lesions compared to the previous imaging, and an overall partial response (figure 4). The case is still under follow-up.

4. Discussion

DSRCTs were identified and characterized by Gerald and Rosai in 1989 [9]. The mean age of diagnosis is approximately between 19 and 22 years, ranging from 6 to 49 years, with a male predominance of 75% [5,10]. In accordance, the present case was a male in his forties. However, Baydar et al. reported 11 cases of primary renal DSRCT, of which seven were females and presented with gross haematuria and abdominal pain [3]. The abdominal cavity is the most common site for tumor

development [5]. This rare malignant soft tissue tumor is associated with a poor prognosis and extreme aggressiveness. The median survival rate is merely 2 years, and cases exceeding 40 months seem exceptionally rare. Out of 35 cases in Giani et al' study, only 5 cases (15%) were long-term survivors with a

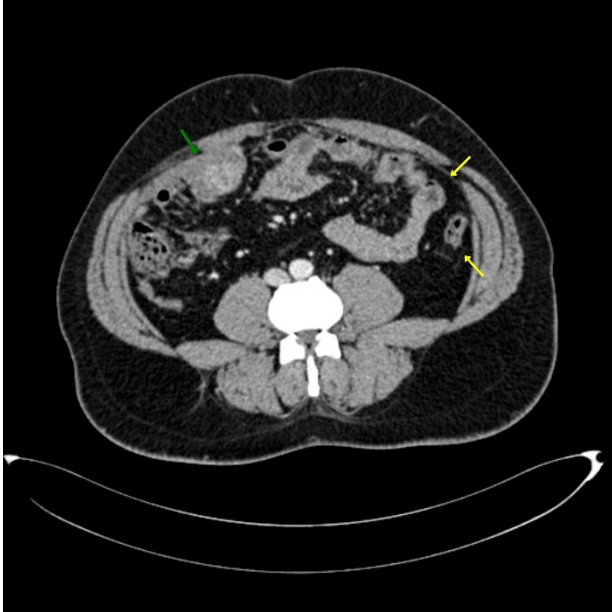


Figure 4. Follow-up abdominal CT with IV contrast after eight months, the right lower abdominal mass shows a marked reduction in size (green arrow), while the left lower abdominal masses have completely regressed (yellow arrows).

median follow-up of 53 months [8,11]. On the other hand, a 21-year-old Japanese girl could survive for over 10 years [12]. The current case is still under follow-up and after 8 months, he partially responded to the treatment regimen. Spherical cell nests surrounded by sclerotic connective tissue may exhibit neural, epithelial, and mesenchymal markers. The molecular marker for this disease is the EWS-WT1 fusion protein. This fusion protein is believed to be the driving force behind the proliferation and progression of DSRCT, activating downstream biological pathways such as vascular endothelial growth factor, platelet-derived growth factor, and transforming growth factor-beta, all of which contribute to the proliferation of DSRCT [8,9]. While DSRCT is thought to originate from multi-phenotypic progenitor cells belonging to the "small round blue cell tumors" family, molecular biology analysis confirms it as a distinct tumor. Despite co-expression of epithelial, mesenchymal, myogenic, and neural markers, the translocation (t11;22) (p13;q12), resulting in the fusion of EWSR1 and WT1 genes, triggers a molecular cascade leading to upregulation of PDGFR α . This hallmark phenomenon is unique to DSRCT [3].

In cases of DSRCT, CT scans, magnetic resonance imaging (MRI), and abdominal ultrasounds reveal multiple peritoneal masses ranging from millimeter-sized nodules to nodules exceeding 20 cm. CT scans are commonly employed for comprehensive staging and the search for visceral metastasis (hepatic and/or pulmonary) [6]. The CT scan of the abdomen and pelvis, in this case, revealed multiple enhancing soft tissue

nodules distributed diffusely throughout the peritoneal cavity. Furthermore, a conglomerated mass on the right side of the mid-abdomen was found just under the anterior abdominal wall and a mass was observed in the retrovesical region. Recurrence or progression in DSRCT is frequent, even after complete cytoreductive surgery, often manifesting within the peritoneum due to challenges in achieving complete removal of microscopic residual tumors [11]. Diagnosis of DSRCT is intricate due to its rarity in clinical practice and the lack of definitive treatment in the literature. Intraperitoneal metastasis is present in 90% of DSRCT cases, and extraperitoneal metastasis is present in 25–43% [8]. Both intraperitoneal and extraperitoneal metastases are common findings in DSRCT and Ewing's sarcoma. In the present case, the tumor invaded the pelvis, rectum, and retrovesical region. As in our case, another study reported that in 82% of the cases, lesions can be found in the rectum [2]. Biopsies from internal and external peritoneal lesions are essential for accurate diagnosis. Histological analysis of lesion biopsies typically reveals small round blue cells encircled by desmoplastic stroma, a hallmark of DSRCT diagnosis [6]. In our case, biopsies exhibited cell nests with similar characteristics to other studies [2,6,12], leading to a diagnosis of DSRCT.

Currently, a universally accepted treatment protocol for patients diagnosed with DSRCT remains unavailable, despite the prevalent utilization of an aggressive multimodality approach. This prevailing uncertainty is rooted in outcomes exclusively gleaned from retrospective analyses, which frequently yield conflicting results. Primary interventions for the treatment of the primary tumor encompass a combination of multiagent chemotherapy, comprehensive cytoreductive surgery, and, in certain instances, post-operative whole abdominopelvic radiotherapy along with maintenance chemotherapy [6,11,13,15]. HIPEC chemotherapy has been suggested as a treatment of choice in some studies, yet contradictions in results raise concerns about its effectiveness. Aggressive surgical debulking is also proposed as a therapeutic cornerstone [6]. Updated data suggests HIPEC alone doesn't yield survival benefits and its uncertainties and mixed results cast doubts on its overall effectiveness, potentially leading to disadvantages in some patients [11,13]. This underscores the need for further research on HIPEC's potential benefits. Chemotherapy combinations including anthracyclines, ifosfamide/cyclophosphamide, cisplatin, and etoposide have shown better prognosis than other regimens [11]. Our chosen chemotherapy treatment (VAC-IE) included many components found effective and may give insights for future investigation of this regimen in treating the disease.

Debulking surgery and tumor resection have demonstrated increased survival rates, but this approach is suitable only for patients lacking liver or extraperitoneal metastasis, as it could negatively impact those with such metastases, raising mortality rates [13].

The high male-female ratio is another topic of discussion. Data shows not only males are more susceptible to DSRCT, but they also experience a poorer prognosis. Androgen receptors are implicated in enhancing DSRCT progression, and high dihydrotestosterone levels are linked to worsened prognosis. Anti-androgen use in one trial resulted in a 3 to 4-month benefit

for patients with DSRCT [2,14]. The most successful case reported in literature involves a 21-year-old female in Japan diagnosed with DSRCT at age 10, surviving disease-free for a decade. Favorable conditions and chemotherapy responses likely contributed to her positive outcome, which aligns with our case to some extent [15]. Our patient was diagnosed with DSRCT on September 11th, 2022, and has received 16 VAC-IE chemotherapy cycles every 21 days since. After 8 months, CT scans conducted on May 30th, 2023, showed resolved hepatic lesions and no new lesions compared to previous imaging, indicating an overall partial response. For validating our references, they have all been checked [16]. Our study is limited by the inability to provide ultrasound images.

5. Conclusion

DSRCT remains under-researched, with a lack of definitive treatment. VAC-IE chemotherapy has shown positive outcomes in 8 months. Further studies with proper study design on the efficacy of VAC-IE chemotherapy in treating DSRCT are essential.

Declarations

Conflicts of interest: The author(s) have no conflicts of interest to disclose.

Ethical approval: Not applicable.

Patient consent (participation and publication): Written informed consent was obtained from the patient for participation in the present study and the publication of the present case report and any accompanying images.

Funding: The present study received no financial support.

Acknowledgements: None to be declared.

Authors' contributions: RHA, SMA participated in data collection, designed the study. SNM participated in preparing the manuscript. DTG, ZBN, HRA, DAI and OHH critically revised the manuscript, literature review. RMA was the pathologist examining the specimen. SHT was the radiologist who performed the assessment of the case. SNM, RHA confirmed the authenticity of the data. All authors approved the final version of the manuscript.

Data availability statement: Note applicable.

References

- Zana H, Mahmood, Fenk M, Mohamed, Binaiy N, Fatih, Abdullah A, Qadir, Shalaw H, Abdalla. Cancer publications in one year (2022); a cross-sectional study. *Barw Medical Journal*. 2023;1(2). DOI: N/A
- Al Taei TH, Al Fardan H, Al Mail SA. Intra-abdominal desmoplastic small blue round cell tumor: A case report. *Radiology Case Reports*. 2022;17(12):4502-5. [doi:10.1016/j.rader.2022.09.022](https://doi.org/10.1016/j.rader.2022.09.022)
- Ertoy Baydar D, Armutlu A, Aydin O, Dagdemir A, Yakupoglu YK. Desmoplastic small round cell tumor of the kidney: a case report. *Diagnostic Pathology*. 2020;15(1):1-9. [doi:10.1186/s13000-020-01015-w](https://doi.org/10.1186/s13000-020-01015-w)
- Alfotih S, Zahid H, Mulla N, Wazir KB. Desmoplastic small round cell tumor of abdomen: Case report of a very rare sarcoma with diagnostic challenge. *Literatures*.2021;7: 100084Z10SA2021. [doi:10.5348/100084Z10SA2021CR](https://doi.org/10.5348/100084Z10SA2021CR)
- Feng X, Tao J, Zhou Q, Qiao YD, He LJ, Zhang N. Desmoplastic small round cell tumor of the liver: diagnosing a rare case on liver biopsy. *Diagnostic Pathology*. 2023;18(1):84. [doi:10.1186/s13000-023-01373-1](https://doi.org/10.1186/s13000-023-01373-1)
- Dufresne A, Cassier P, Couraud L, Marec-Bérard P, Meeus P, Alberti L, Blay JY. Desmoplastic small round cell tumor: current management and recent findings. *Sarcoma*. 2012 Oct;2012. [doi:10.1155/2012/714986](https://doi.org/10.1155/2012/714986)
- Honoré C, Delhorme JB, Nassif E, Faron M, Ferron G, Bompas E, et al. Can we cure patients with abdominal desmoplastic small round cell tumor? Results of a retrospective multicentric study on 100 patients. *Surgical Oncology*. 2019; 29:107-12. [doi:10.1016/j.suronc.2019.04.002](https://doi.org/10.1016/j.suronc.2019.04.002)
- Magrath JW, Flinchum DA, Hartono AB, Goldberg IN, Espinosa-Cotton M, Moroz K, et al. Genomic Breakpoint Characterization and Transcriptome Analysis of Metastatic, Recurrent Desmoplastic Small Round Cell Tumor. *Sarcoma*. 2023;2023. [doi:10.1155/2023/6686702](https://doi.org/10.1155/2023/6686702)
- Gerald WL, Rosai J. Case 2 desmoplastic small cell tumor with divergent differentiation. *Pediatric pathology*. 1989 Jan 1;9(2):177-83. [doi:10.3109/15513818909022347](https://doi.org/10.3109/15513818909022347)
- Luke E. Pater, John Breneman, Chapter 75 – Rare Pediatric Tumors, Editor(s): Leonard L. Gunderson, Joel E. Tepper, Clinical Radiation Oncology (Fourth Edition), Elsevier,2016, Pages 1486-1500.
- Giani C, Radaelli S, Miceli R, Gandola L, Sangalli C, Frezza AM, Provenzano S, Pasquali S, Bertulli R, Fiore M, Callegaro D. Long-term survivors with desmoplastic small round cell tumor (DSRCT): Results from a retrospective single-institution case series analysis. *Cancer Medicine*. 2023;12(9):10694-703. [doi:10.1002/cam4.5829](https://doi.org/10.1002/cam4.5829)
- Saleh D, Al-Maghrabi S, Al-Maghrabi H, Al-Maghrabi J. Desmoplastic small round cell tumor of pancreatic origin in a young child: a case report and review of literature. *The American Journal of Case Reports*. 2020;21: e922762-1. [doi:10.12659/AJCR.922762](https://doi.org/10.12659/AJCR.922762)
- Reijers SJ, Siew CC, Kok NF, Honoré C, van Houdt WJ. Intra-Abdominal Desmoplastic Small Round Cell Tumor (DSRCT) and the Role of Hyperthermic Intraperitoneal Chemotherapy (HIPEC): A Review. *Current Oncology*. 2023;30(4):3951-63. [doi:10.3390/curroncol30040299](https://doi.org/10.3390/curroncol30040299)
- Mello CA, Campos FA, Santos TG, Silva ML, Torrezan GT, Costa FD, et al. Desmoplastic small round cell tumor: a review of main molecular abnormalities and emerging therapy. *Cancers*. 2021;13(3):498-519. [doi:10.3390/cancers13030498](https://doi.org/10.3390/cancers13030498)
- Yamauchi K, Owari M, Kimura K, Ishii T, Wakasa T, Yonekura T. Desmoplastic small round cell tumor: A case report and literature review. *Journal of Pediatric Surgery Case Reports*. 2023 Jul 10:102691. [doi:10.1016/j.epsc.2023.102691](https://doi.org/10.1016/j.epsc.2023.102691)
- Muhaldeen AS, Ahmed JO, Baba HO, Abdullah IY, Hassan HA, Najar KA, et al: Kscien's List; A New Strategy to Discourage Predatory Journals and Publishers (Second Version). *Barw Med J*.2023; 1 (1): 1-3. [doi:10.58742/BMJ.V1I1.14](https://doi.org/10.58742/BMJ.V1I1.14)